

# Anatomy and Physiology II

## Shoulder Girdle

# Bones

- Scapula (pgs200-201)
- Clavicle
- Proximal end of Humerus

# Scapula

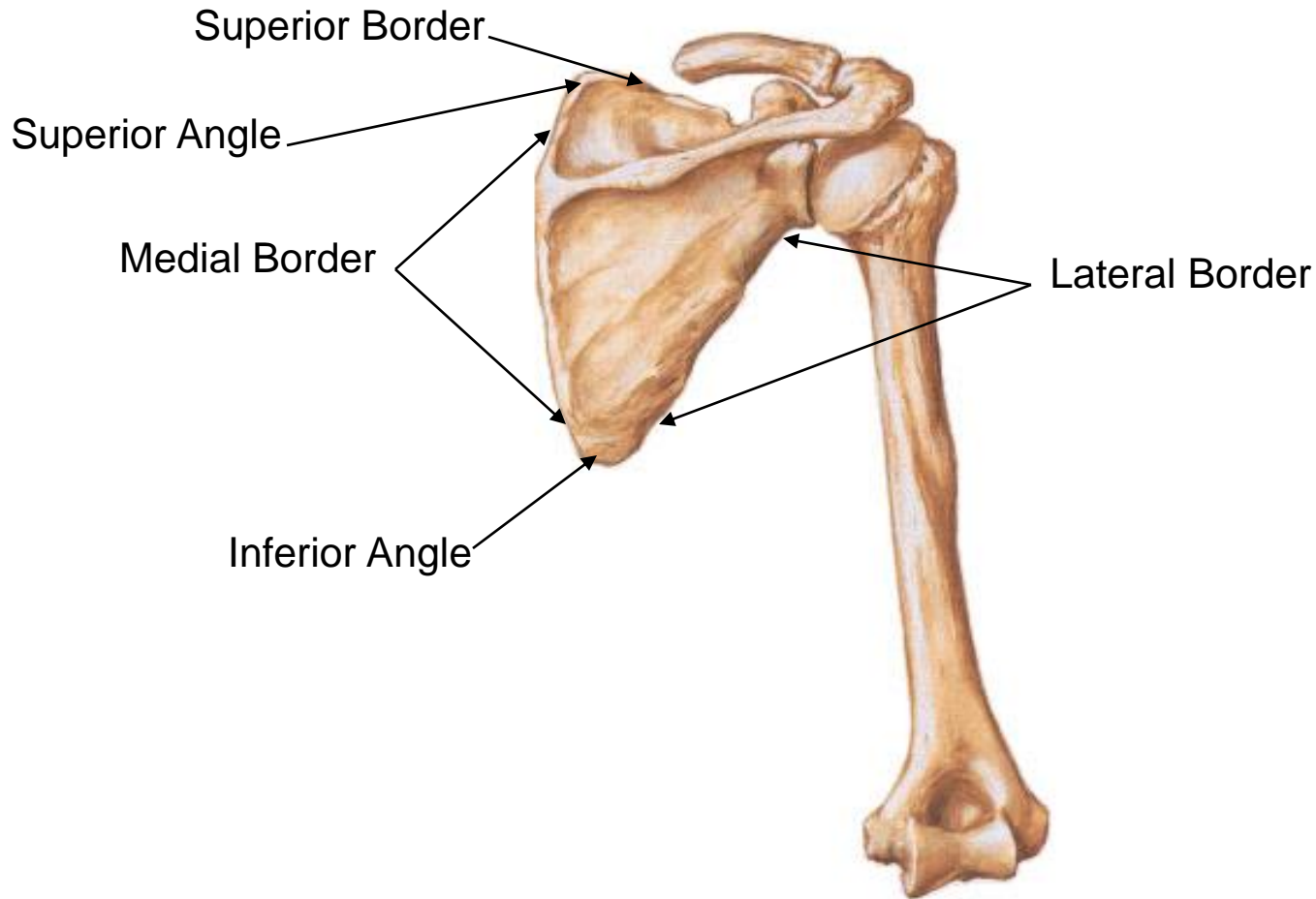
- Landmarks
  - Borders
    - Vertebral (medial) border
    - Axillary (lateral) border
    - Superior border
    - Superior angle
    - Inferior angle
  - Processes
    - Acromion
    - Spine (and root of the spine)
    - Coracoid process
  - Depressions
    - Glenoid cavity
    - Supraspinous fossa
    - Infraspinous fossa
    - Subscapular fossa

# Proximal Humerus

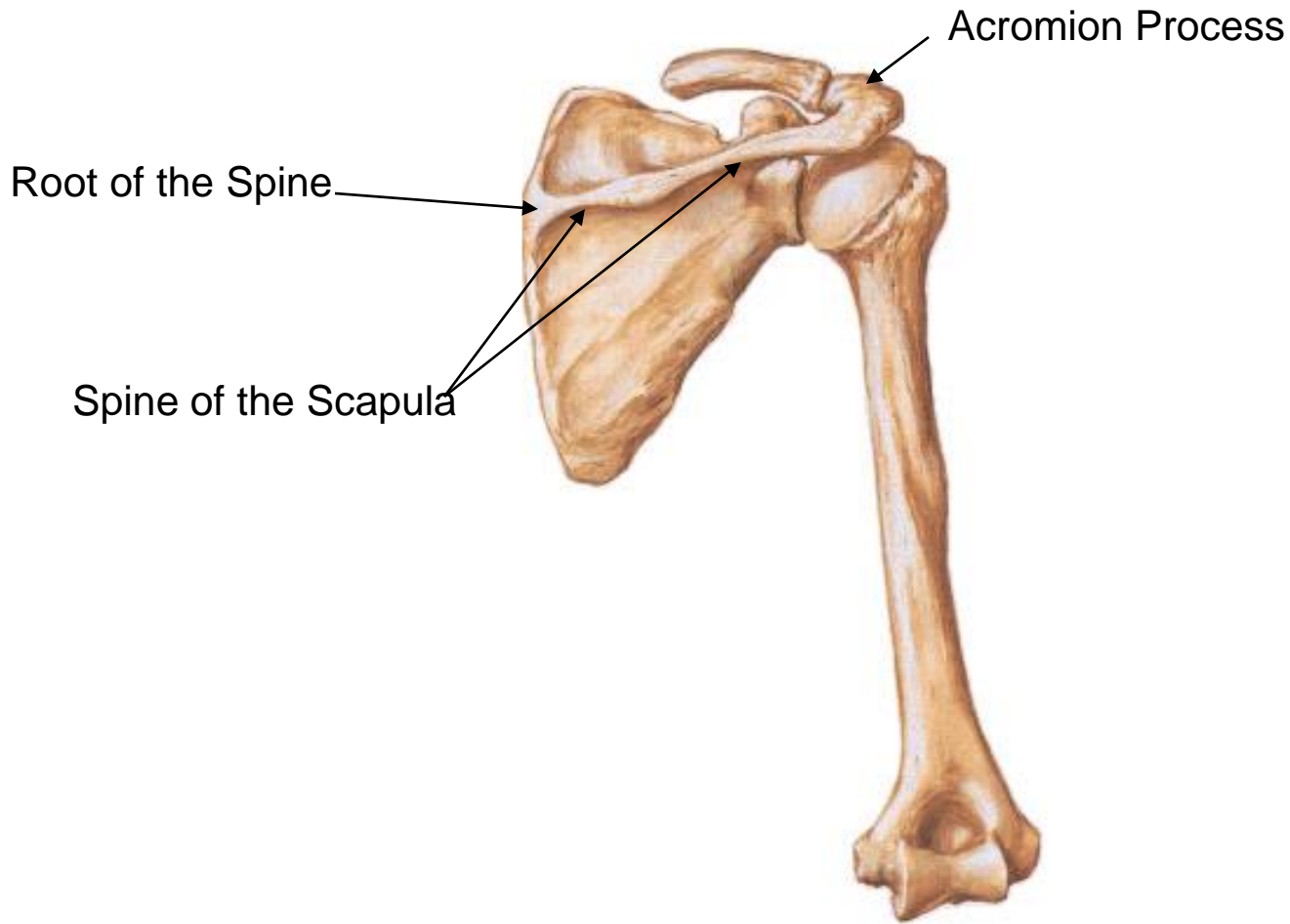
- Landmarks
  - Head
  - Greater tubercle
  - Lesser tubercle
  - Bicipital Groove (intertubercular groove or sulcus)
  - Deltoid tuberosity

# Humerus and Scapula - Borders

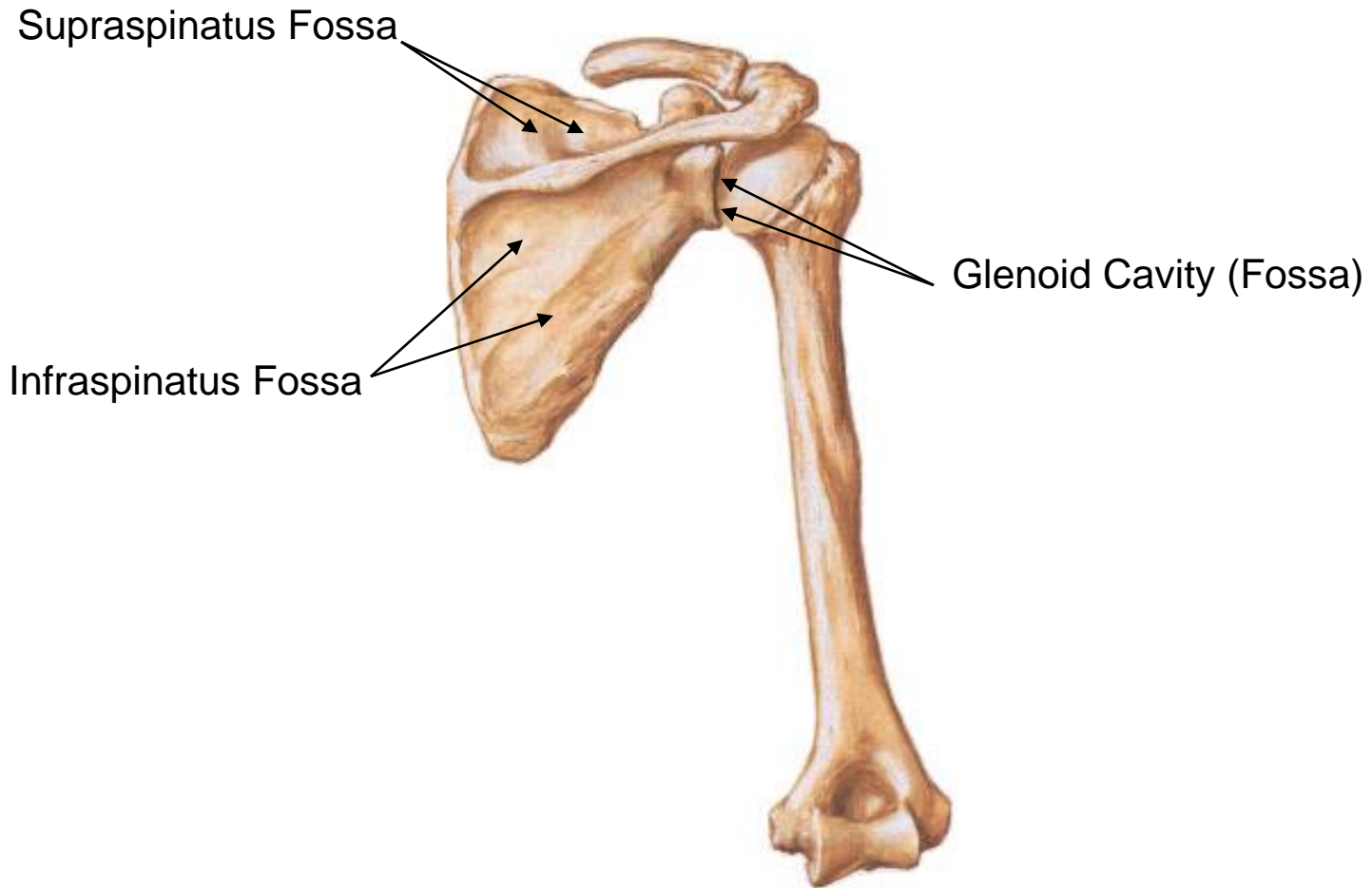
## Posterior View



# Humerus and Scapula - Processes Posterior View

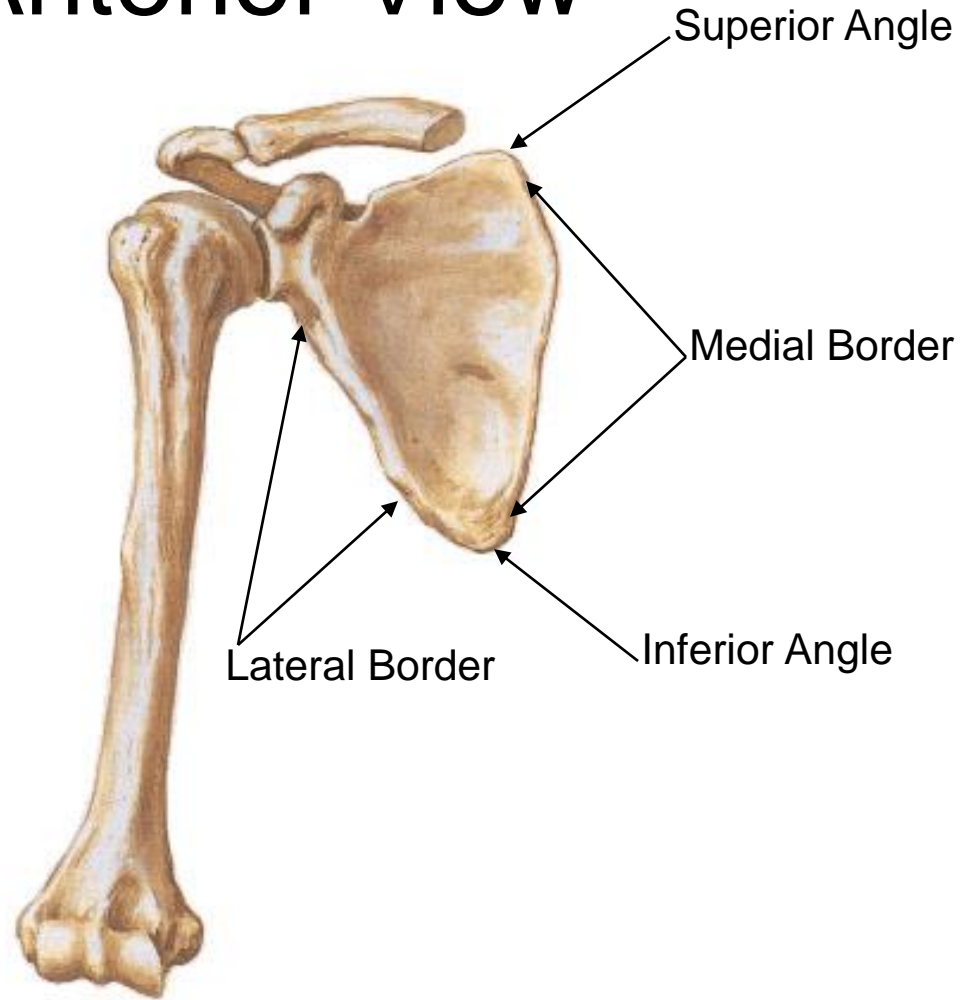


# Humerus and Scapula - Depressions Posterior View



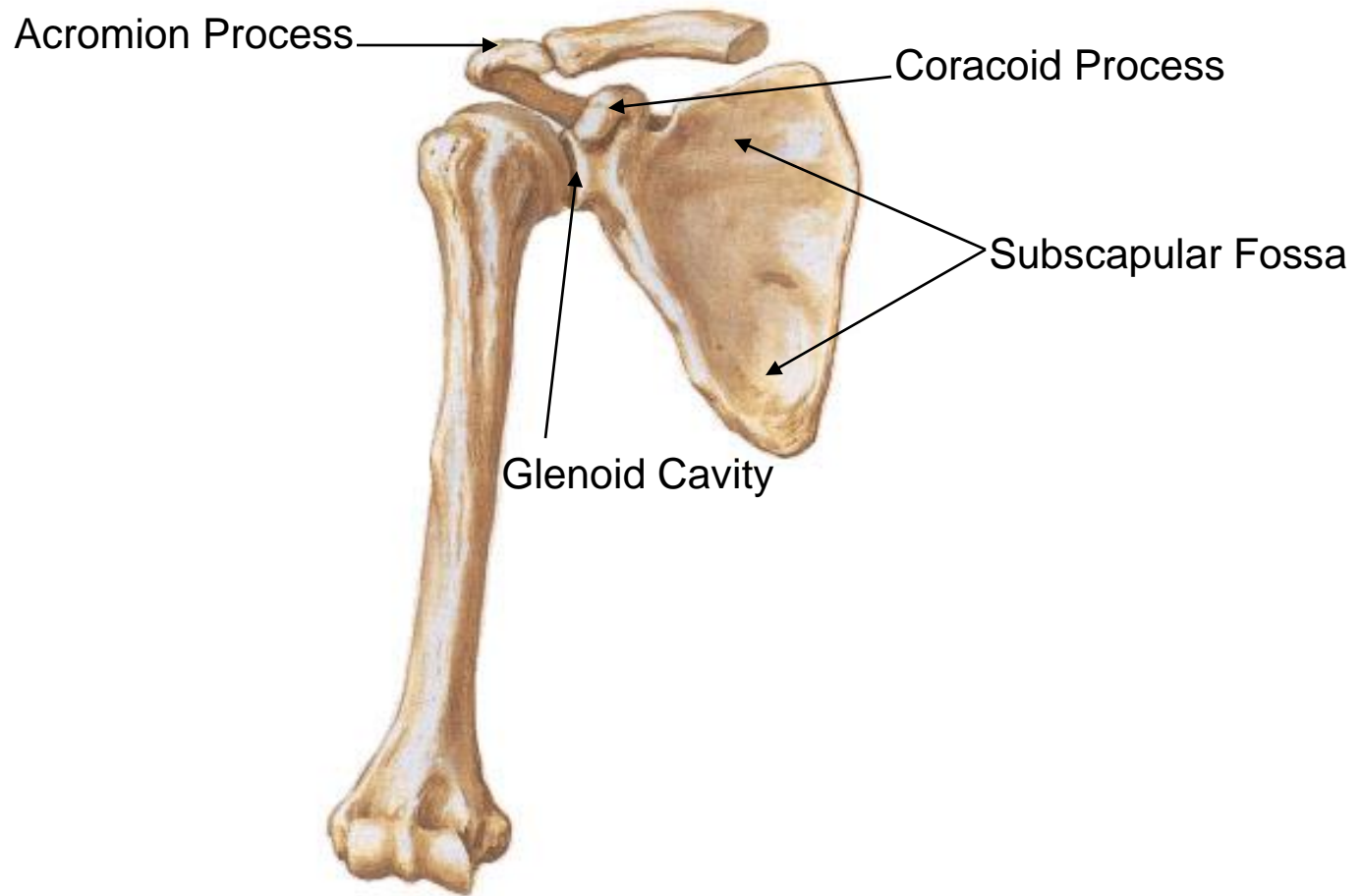
# Humerus and Scapula - Borders

## Anterior View

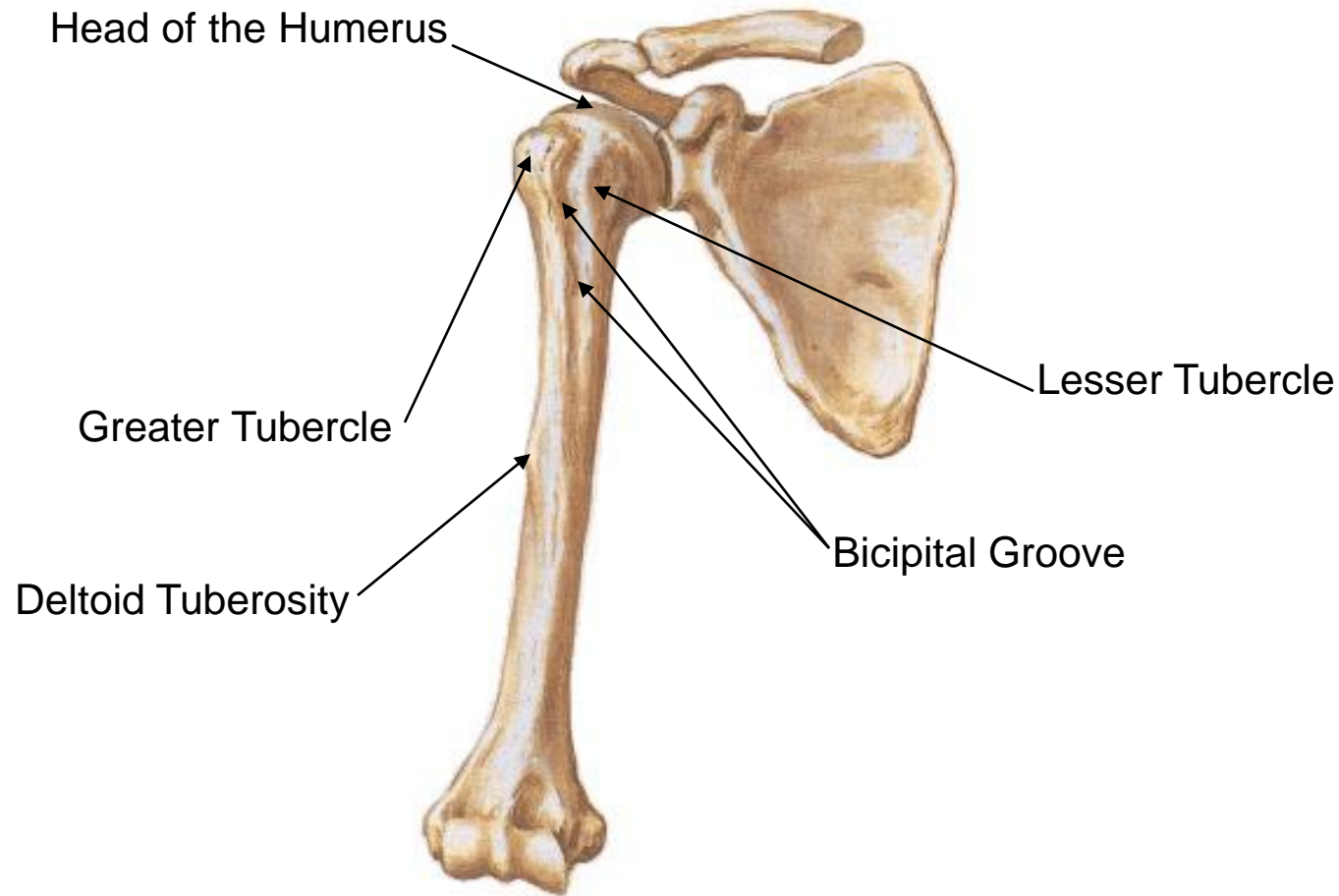




# Humerus and Scapula – Processes and Depressions Anterior View

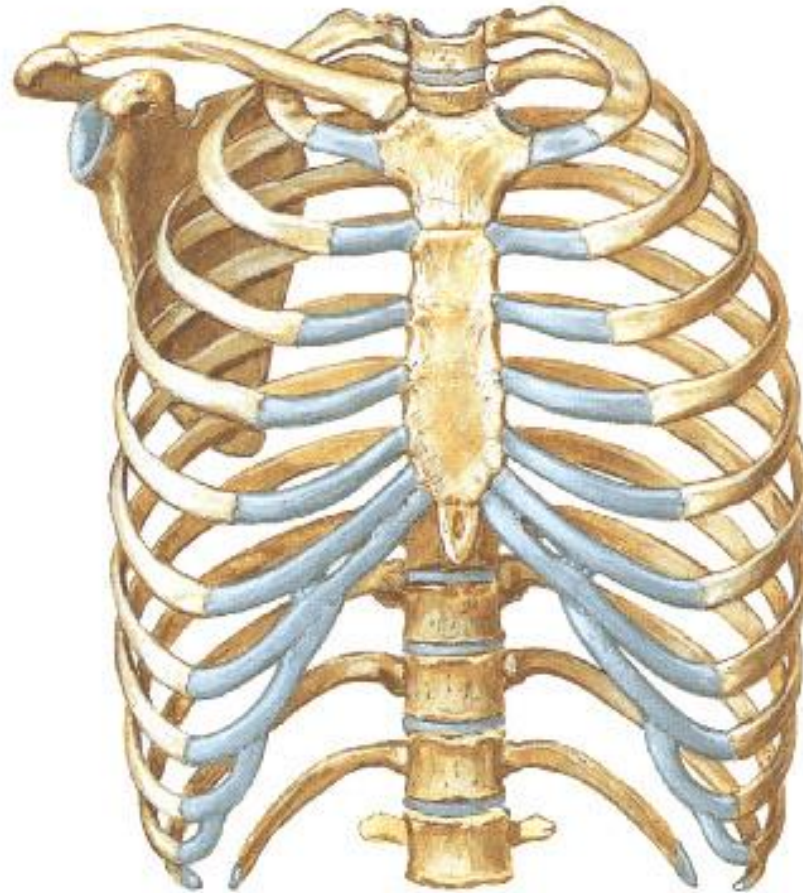


# Humerus and Scapula – Processes and Depressions Anterior View



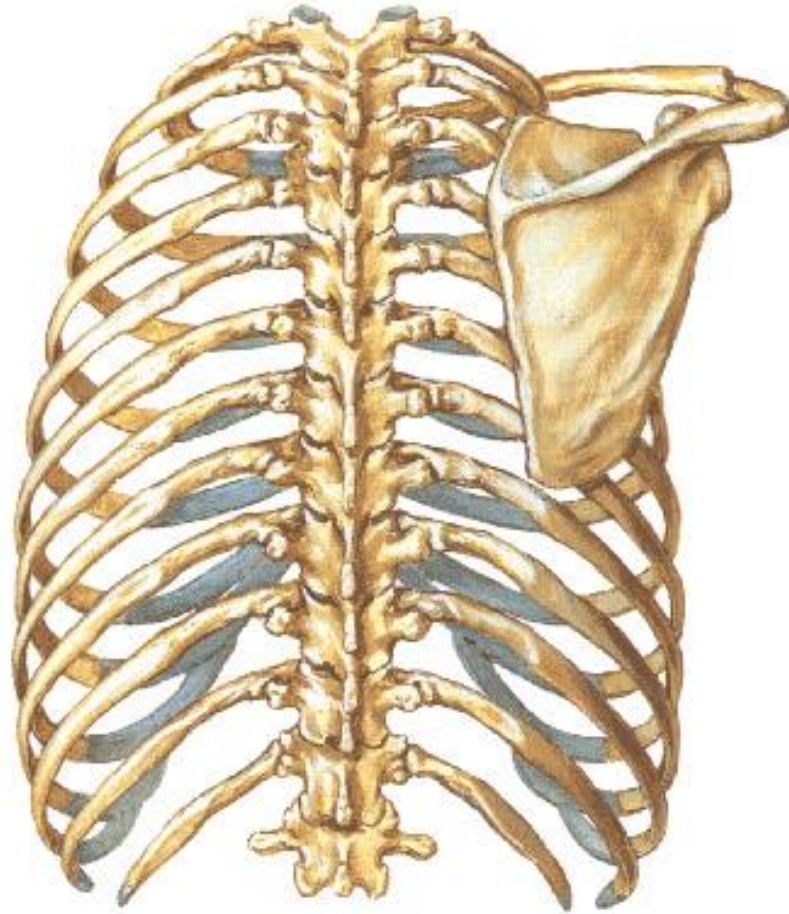# Bony Framework of Thorax

## Anterior View



# Bony Framework of Thorax

## Posterior View



# Joints

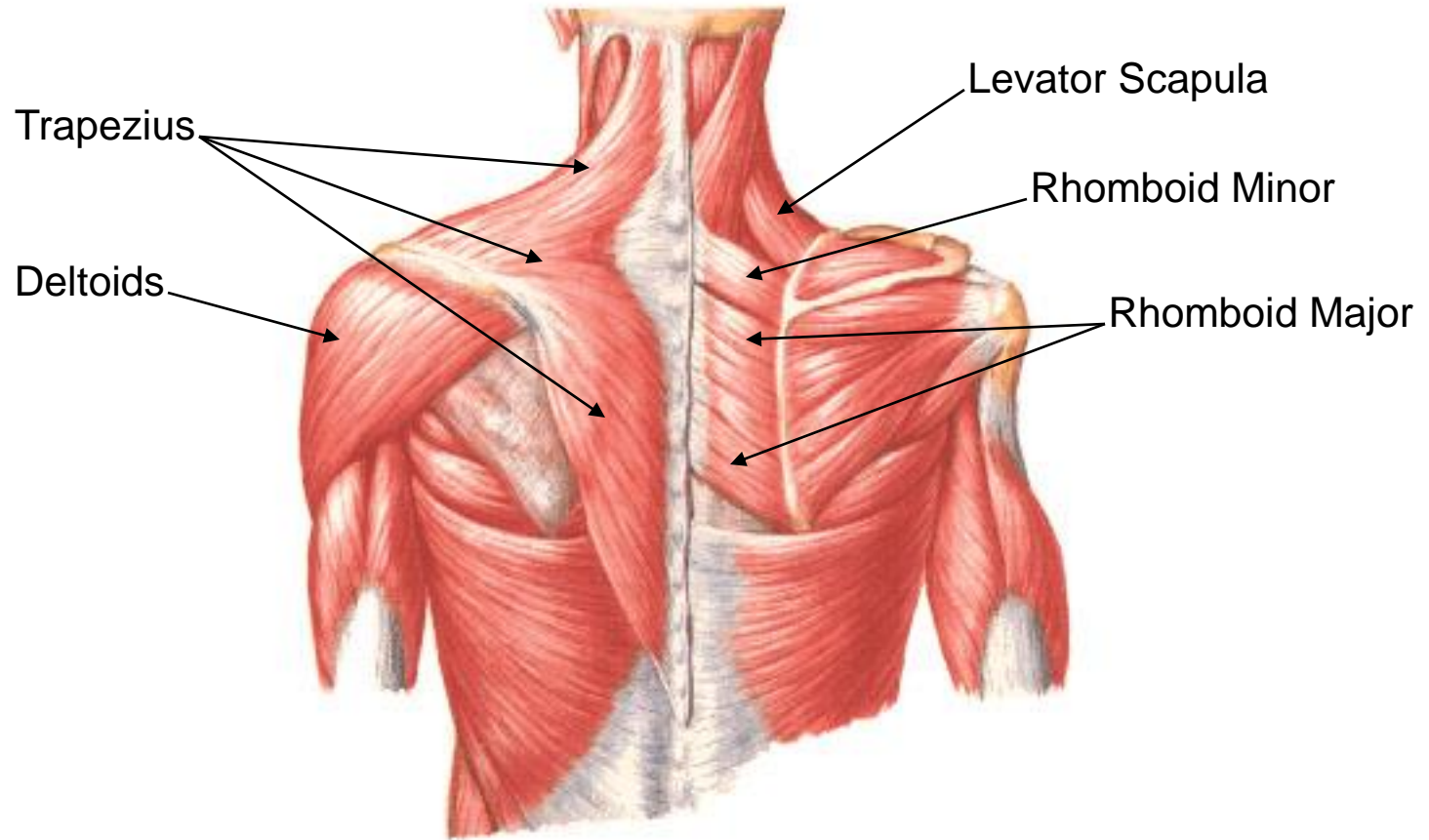
- Glenohumeral joint
  - Between glenoid cavity of scapula and head of humerus
    - Ball and socket joint, very mobile
- Acromioclavicular joint
  - Between acromion of scapula and clavicle
- Sternoclavicular joint
  - Between sternum and clavicle
- Suprhumeral (subacromial) joint
  - Between acromion and humerus
- Scapulocostal (scapulothoracic) joint
  - Between scapula and ribcage
  - Movements include
    - Elevation
    - Depression
    - Retraction (adduction)
    - Protraction (abduction)
    - Upward rotation
    - Downward rotation

# Muscles

- Muscles that position the shoulder girdle
  - Trapezius
  - Levator scapula
  - Rhomboid major and minor
  - Serratus anterior
  - Pectoralis minor
- Muscles that move the arm
  - Deltoids
  - Teres major
  - Latissimus dorsi
  - Pectoralis major
  - Rotator cuff muscles
    - Supraspinatus
    - Infraspinatus
    - Teres minor
    - Subscapularis
  - *Biceps brachii and triceps brachii will be listed with muscles that move the elbow*

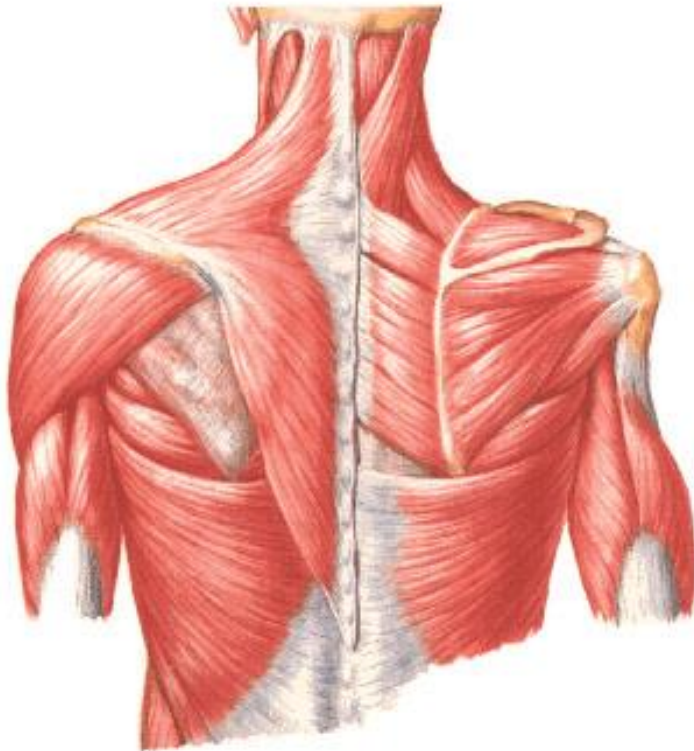
# Muscle of the Shoulder

## Posterior View





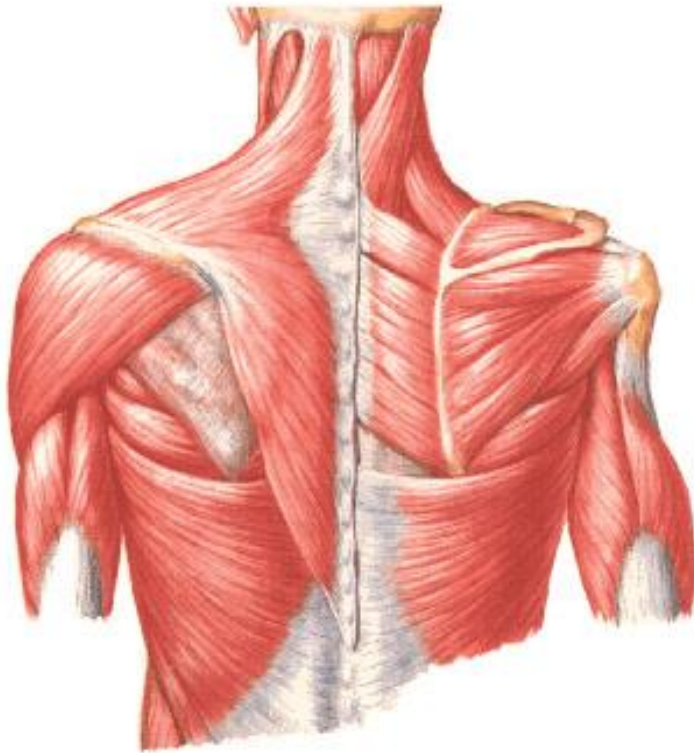
# Trapezius and Deltoids



- Trapezius
  - Attachments
    - External occipital protuberance (EOP), medial 1/3<sup>rd</sup> of the superior nuchal line, nuchal ligament, spinous processes of C7-T12 to the lateral 1/3<sup>rd</sup> of the clavicle, acromion process, and spine of the scapula
  - Action
    - Upper fibers
      - Elevates, retracts and upwardly rotates the scapula
      - Extends, laterally flexes, and contralaterally rotates the head and neck
    - Middle fibers
      - Retracts (adducts) the scapula
    - Lower fibers
      - Depresses, retracts, and upwardly rotates the scapula



# Trapezius and Deltoids



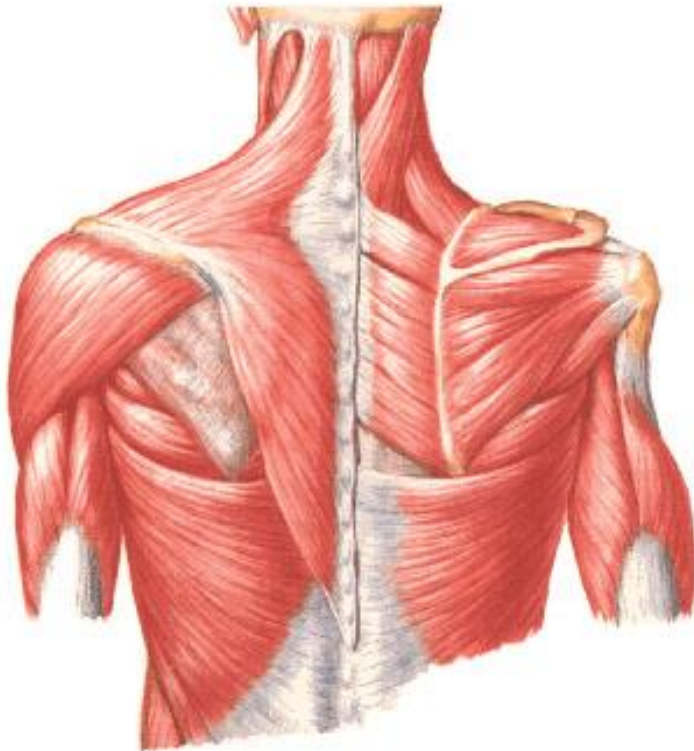
- Deltoids
  - Attachments
    - Lateral 1/3<sup>rd</sup> of the clavicle, acromion process, and spine of the scapula *to the* deltoid tuberosity of the humerus
  - Action
    - Anterior fiber
      - Flexes, abducts, medially rotates, and horizontally flexes the arm at the shoulder joint
    - Middle fibers
      - Abducts the arm at the shoulder joint
    - Posterior fibers
      - Extends, abducts, laterally rotates, and horizontally extends the arm at the shoulder joint

# Rhomboids and Levator Scapula



- Rhomboids
  - Attachments
    - Spinous processes of C7-T5 to the medial border of the scapula from the root of the spine to the inferior angle
  - Action
    - Retracts, elevates and downwardly rotates the scapula

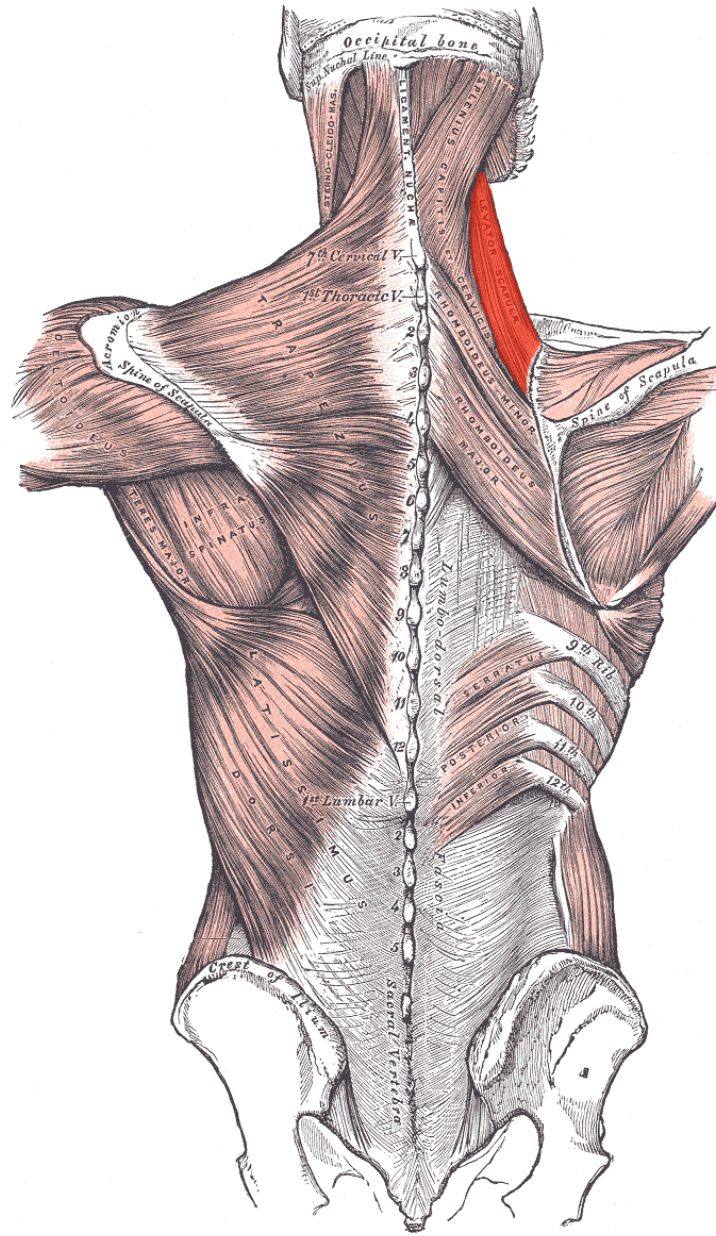
# Rhomboids and Levator Scapula

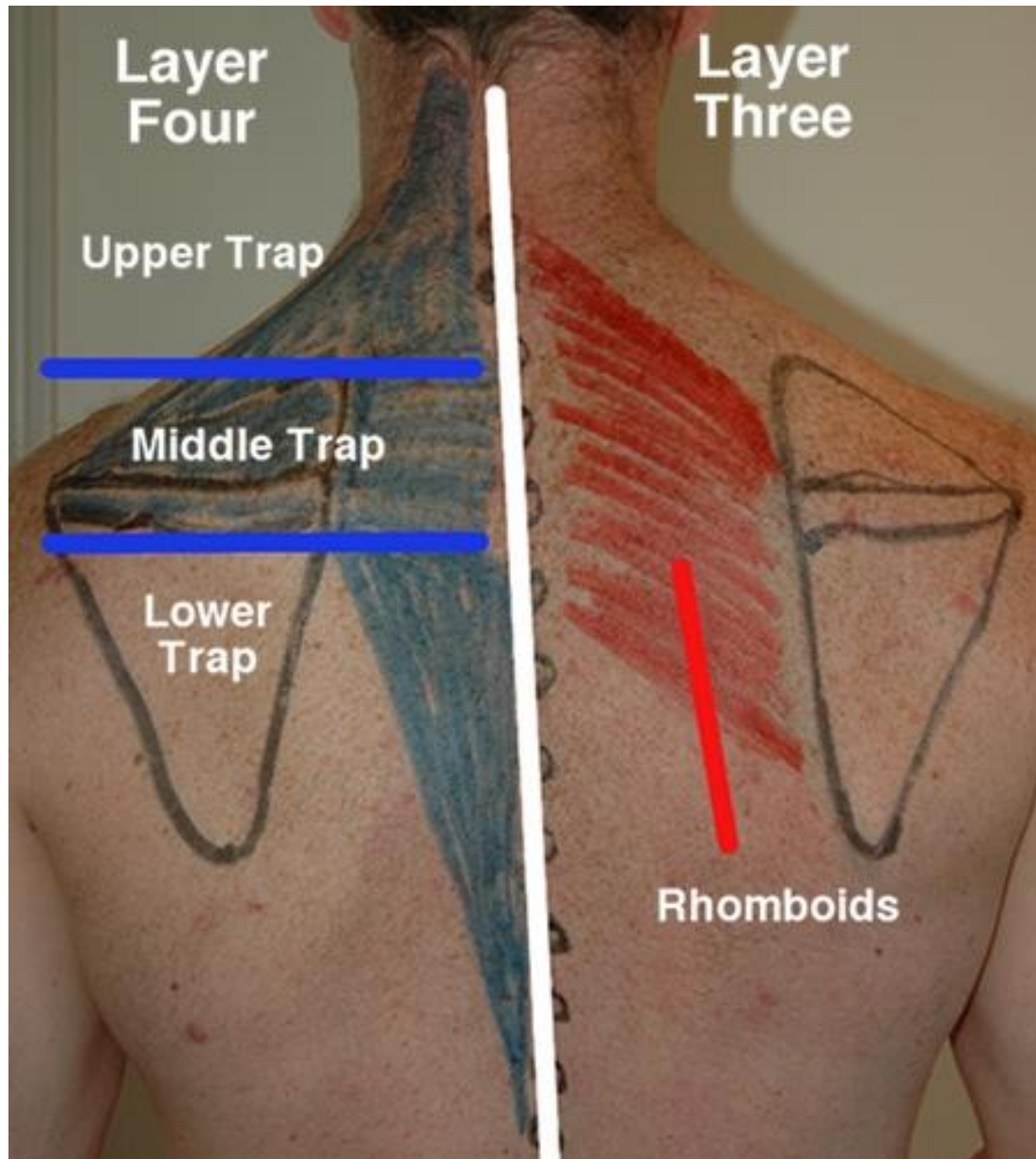


- Levator scapula
  - Attachments
    - Transverse processes of C1 through C4 *to the* medial border of the scapula from the root of the spine to the superior angle of the scapula
  - Action
    - Elevates and downwardly rotates the scapula
    - Extends, laterally flexes, and ipsilaterally rotates the neck









Layer  
Four

Layer  
Three

Upper Trap

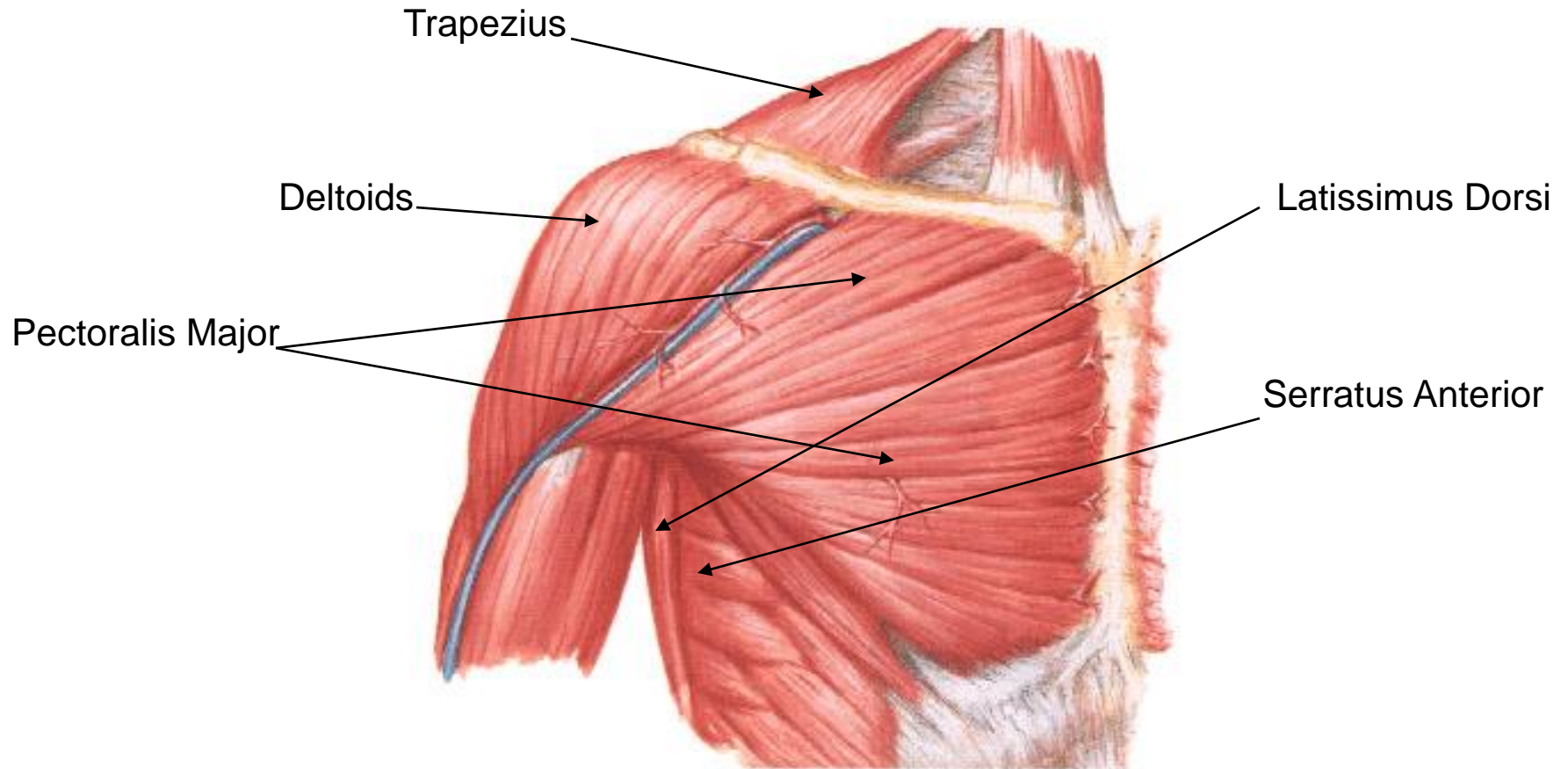
Middle Trap

Lower  
Trap

Rhomboids

# Muscles of the Shoulder

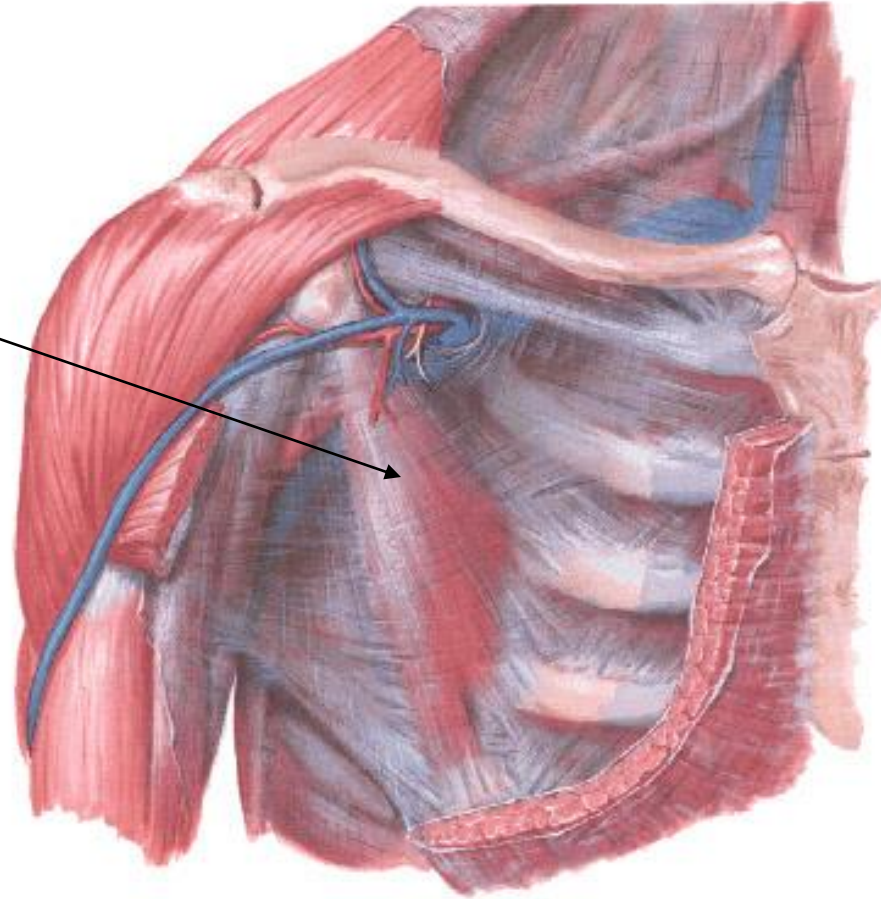
## Anterior View



# Muscles of the Shoulder

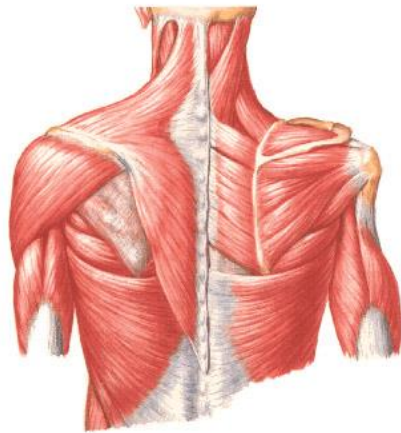
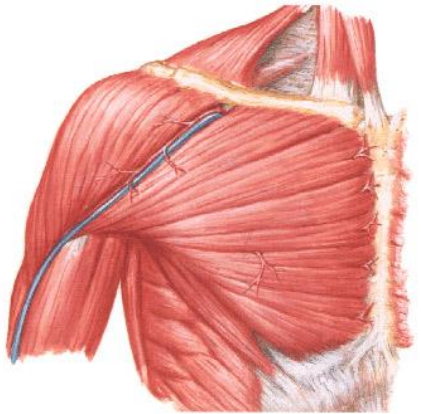
## Deep Anterior View

Pectoralis Minor



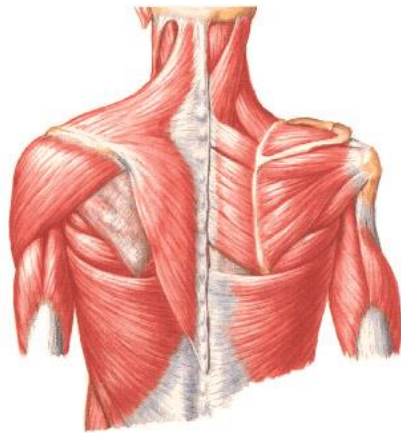
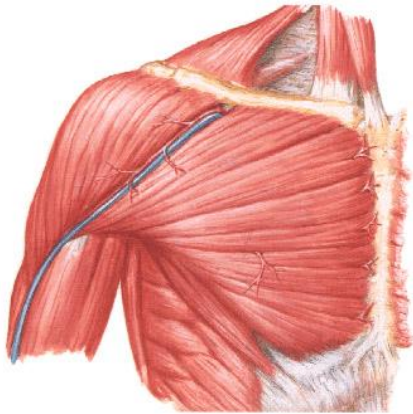


# Pectoralis Major and Latissimus Dorsi



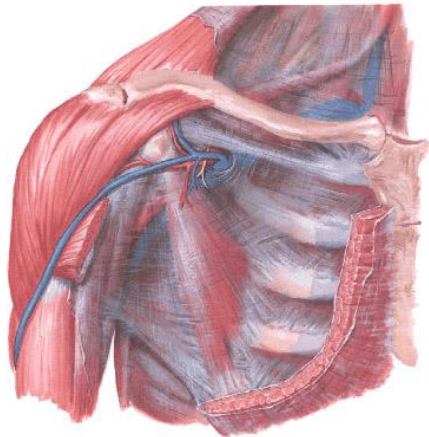
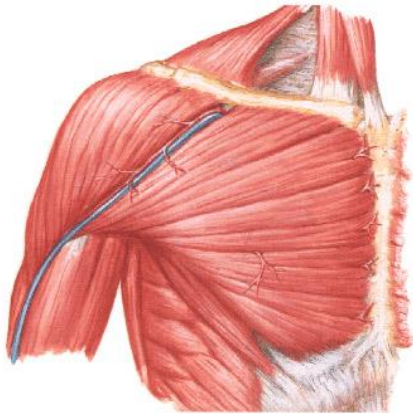
- Pectoralis major
  - Attachments
    - Medial half of the clavicle, sternum, and costal cartilage of the ribs *to the* lateral lip of the bicipital groove of the humerus
  - Action
    - Entire muscle: adducts, medially rotates, and horizontally adducts the arm at the shoulder joint; protracts the scapula
    - Clavicular head: flexes the arm at the shoulder joint
    - Sternocostal head: extends the arm at the shoulder joint (from position of flexion), depresses the scapula

# Pectoralis Major and Latissimus Dorsi



- Pectoralis major
  - Attachments
    - Medial half of the clavicle, sternum, and costal cartilage of the ribs *to the* lateral lip of the bicipital groove of the humerus
  - Action
    - Entire muscle: adducts, medially rotates, and horizontally adducts the arm at the shoulder joint; protracts the scapula
    - Clavicular head: flexes the arm at the shoulder joint
    - Sternocostal head: extends the arm at the shoulder joint (from position of flexion), depresses the scapula

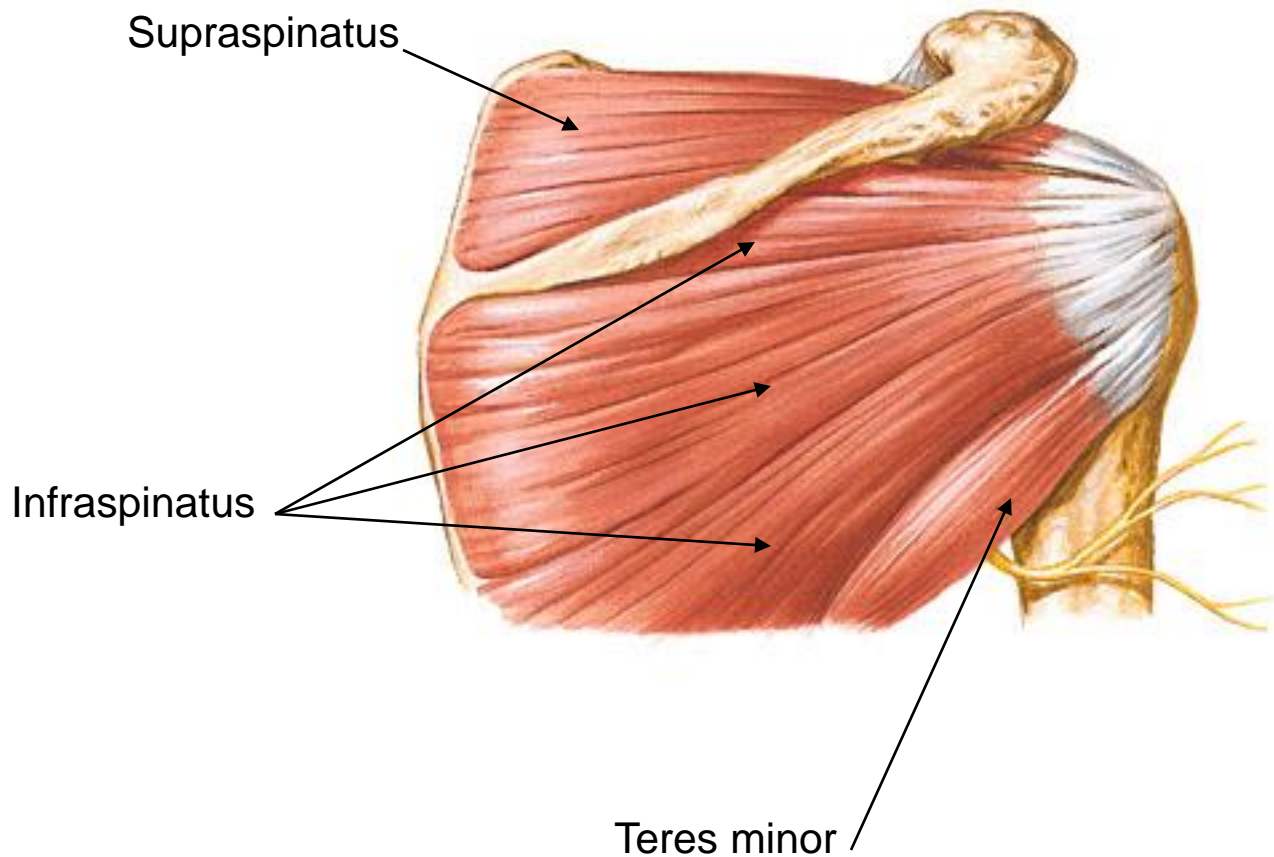
# Pectoralis Major and Minor



- Latissimus Dorsi
  - Attachments
    - Ribs 3-5 *to the* coracoid process of the scapula
  - Action
    - Protracts, depresses, and downwardly rotates the scapula
    - Elevates ribs 3-5



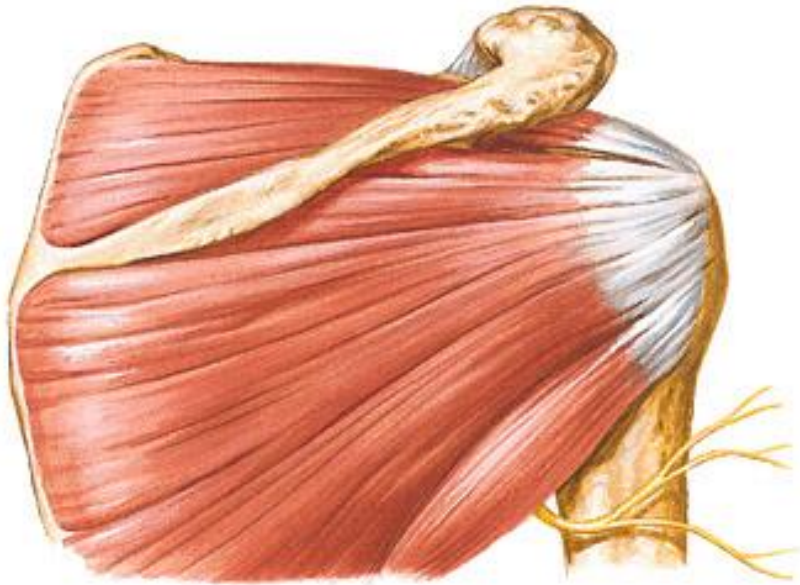
# Muscles of the Rotator Cuff Posterior View





# Muscles of the Rotator Cuff

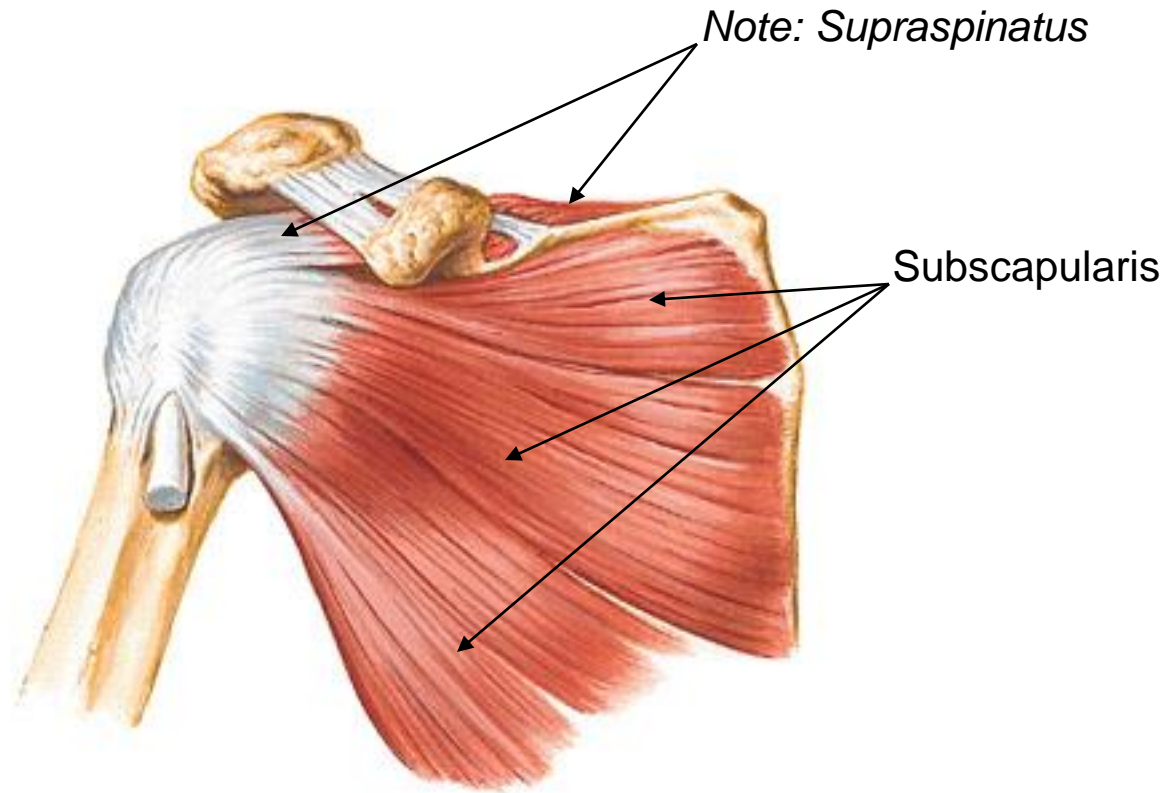
## Posterior View



- Supraspinatus
  - Attachments
    - Supraspinous fossa of scapula *to the* greater tubercle of the humerus
  - Action
    - Abducts the shoulder joint
- Infraspinatus
  - Attachments
    - Infraspinous fossa of the scapula *to the* greater tubercle of the humerus
  - Action
    - Laterally rotates the arm at the shoulder joint
- Teres minor
  - Attachments
    - Superior 2/3rds of the lateral border of the scapula *to the* greater tubercle of the humerus
  - Action
    - Laterally rotates (and adducts) the arm at the shoulder joint

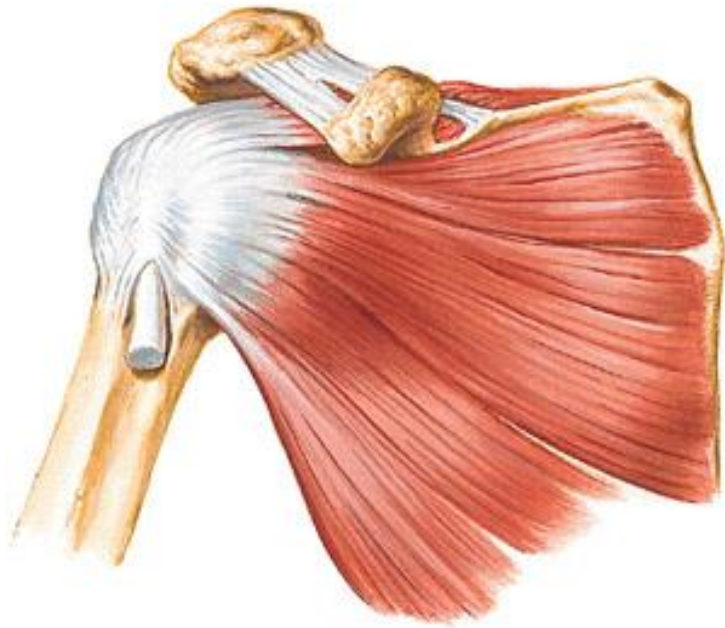
# Muscles of the Rotator Cuff

## Anterior View



# Muscles of the Rotator Cuff

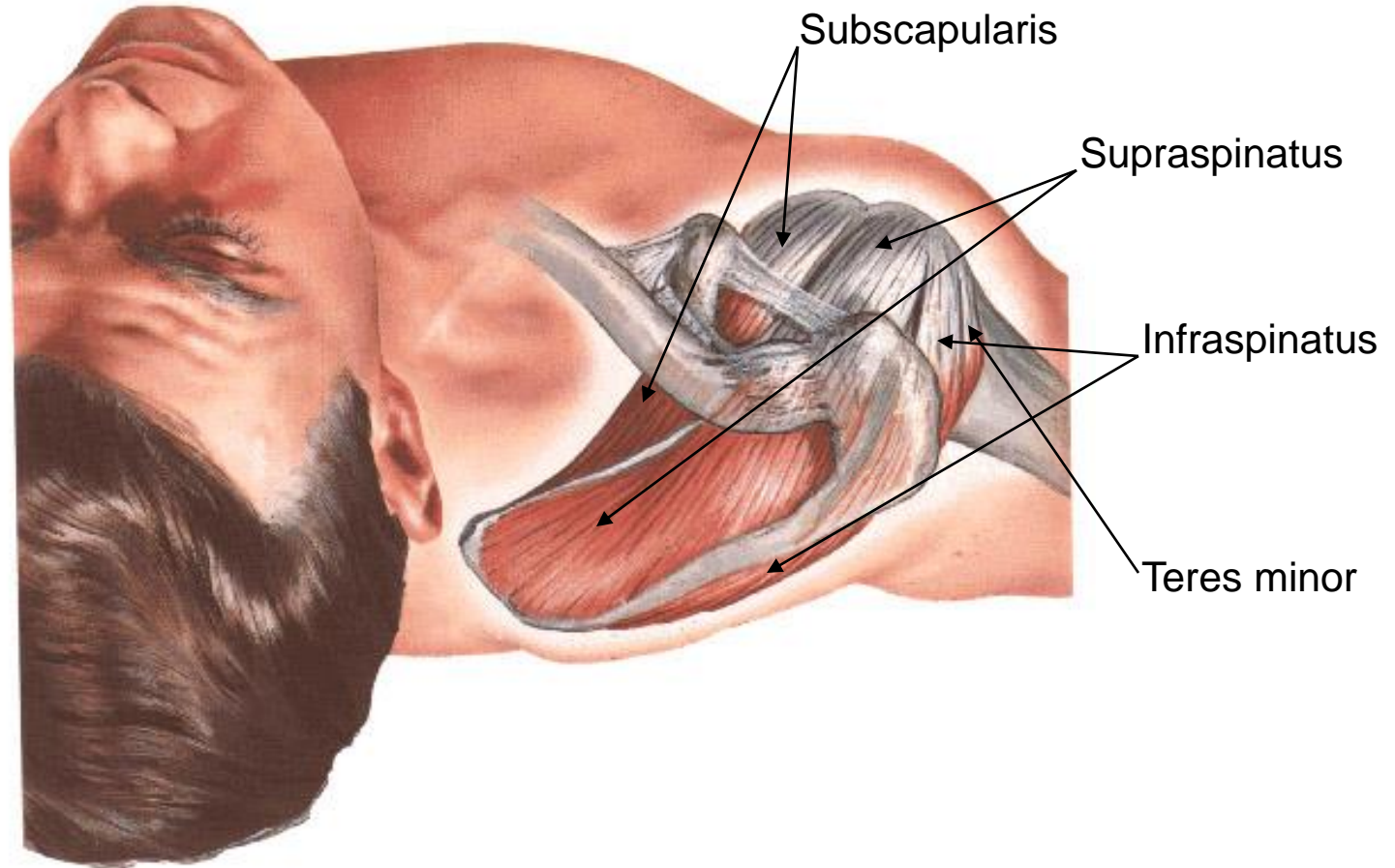
## Anterior View



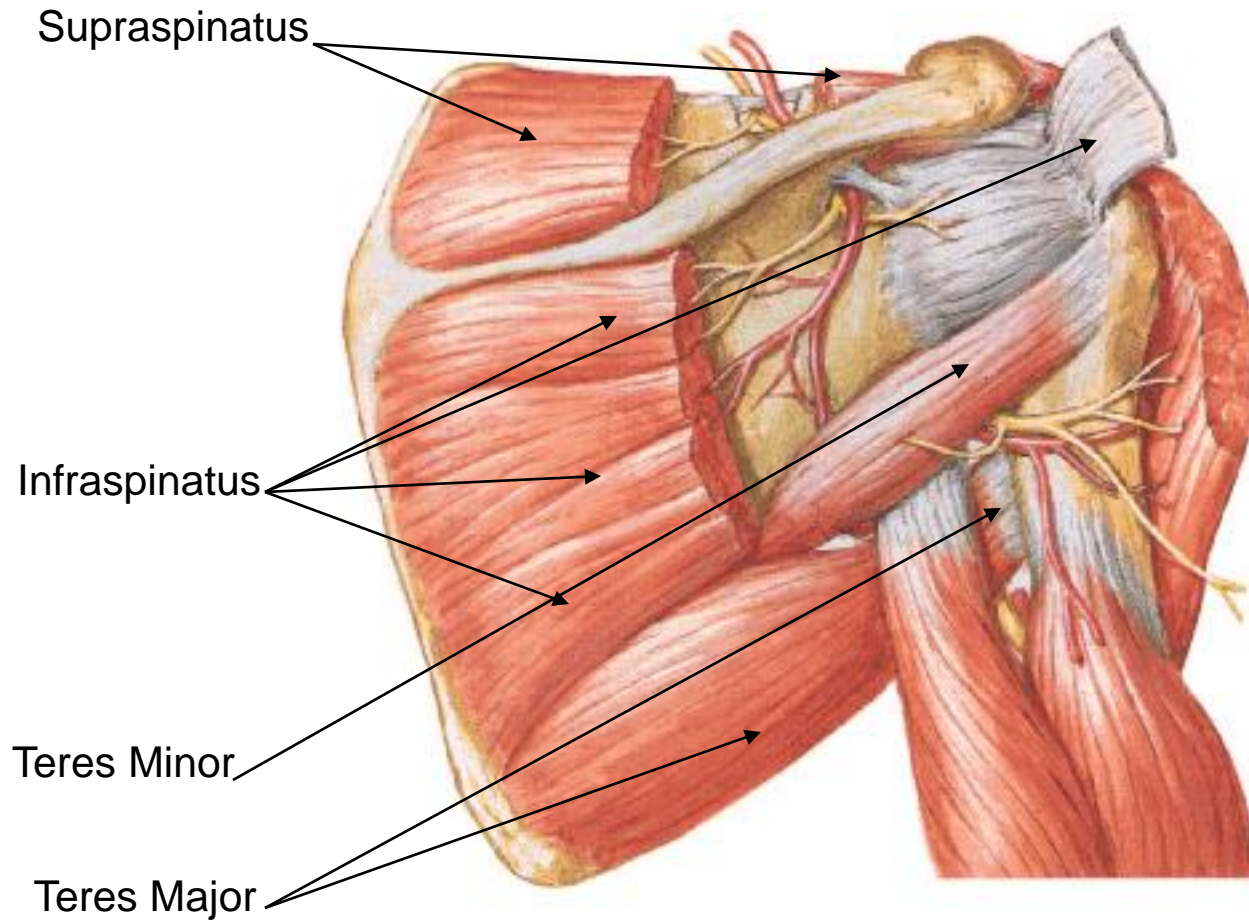
- Subscapularis
  - Attachments
    - Subscapular fossa of the scapula *to the* lesser tubercle of the humerus
  - Action
    - Medially rotates the arm at the shoulder joint



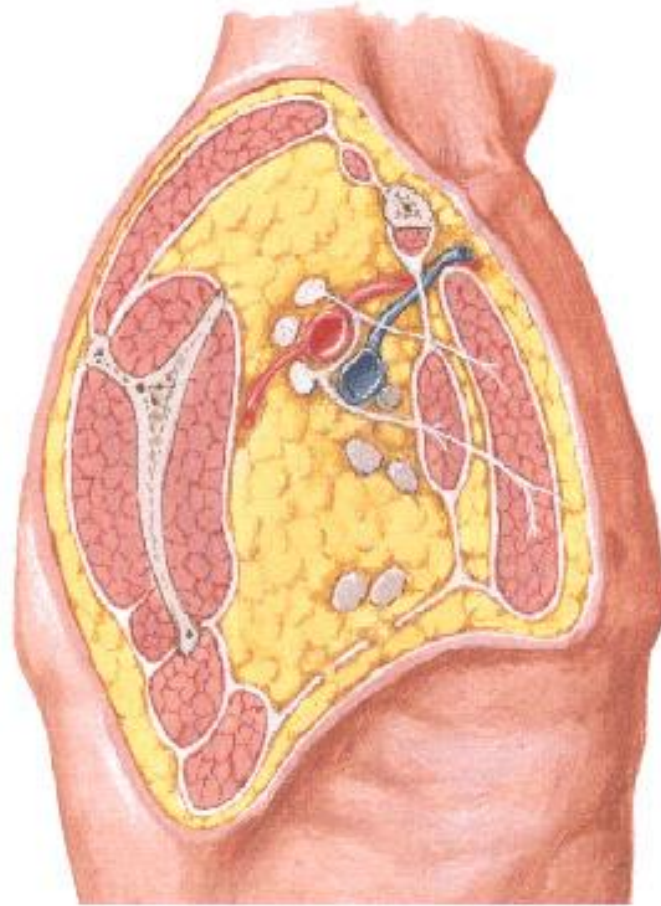
# Muscles of the Rotator Cuff Superior View



# Scapulohumeral Dissection Posterior View

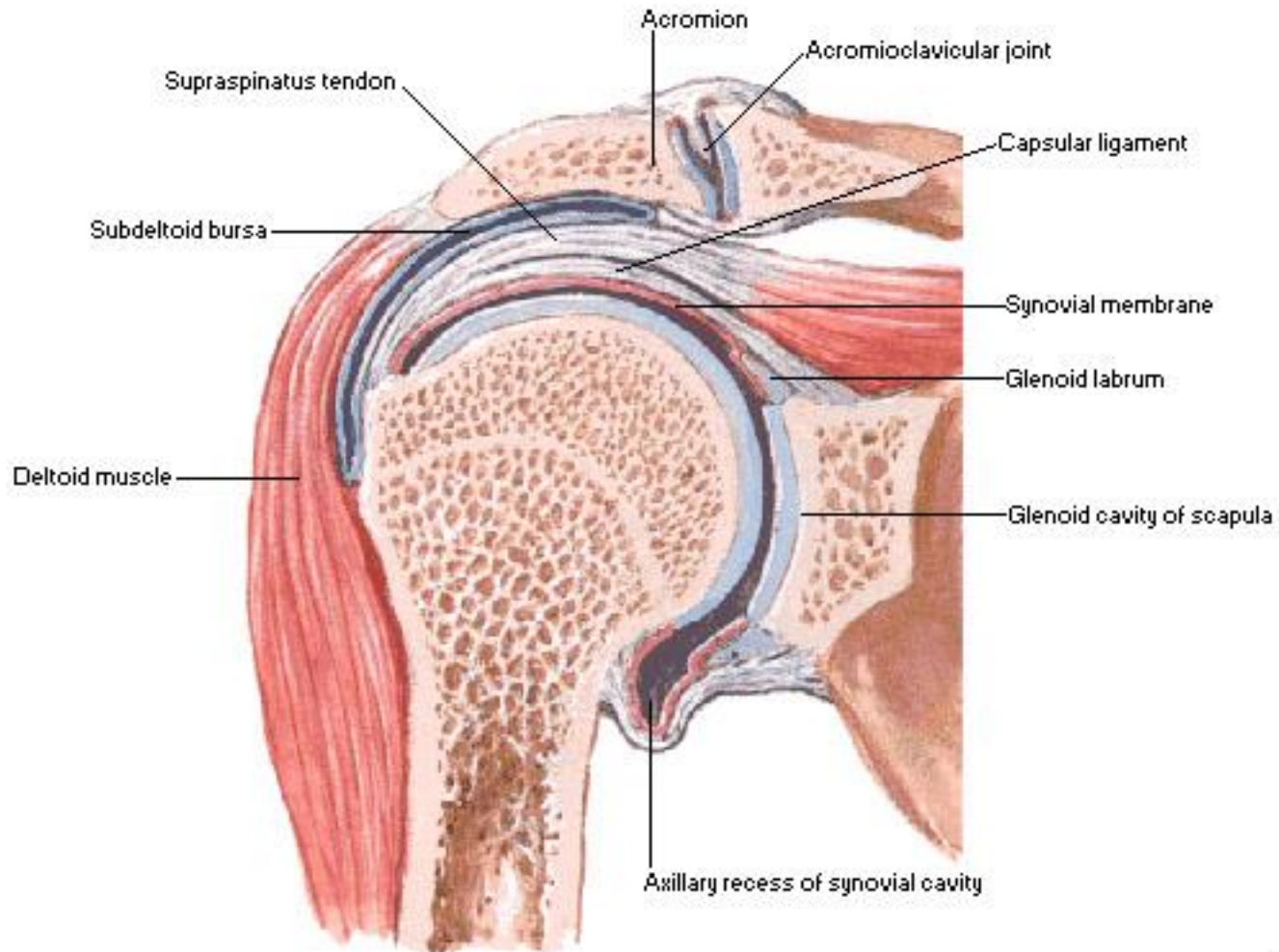


# Parasagittal Section Through the Axilla



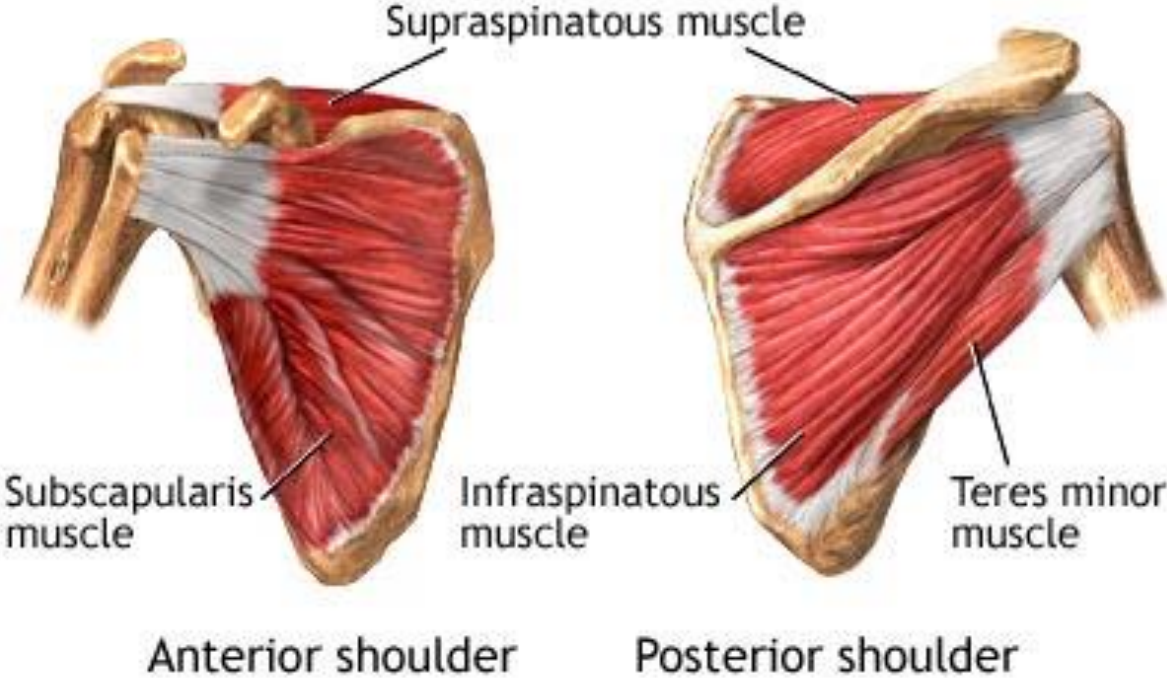
# Shoulder [Glenohumeral] Joint

## Coronal Section through Joint

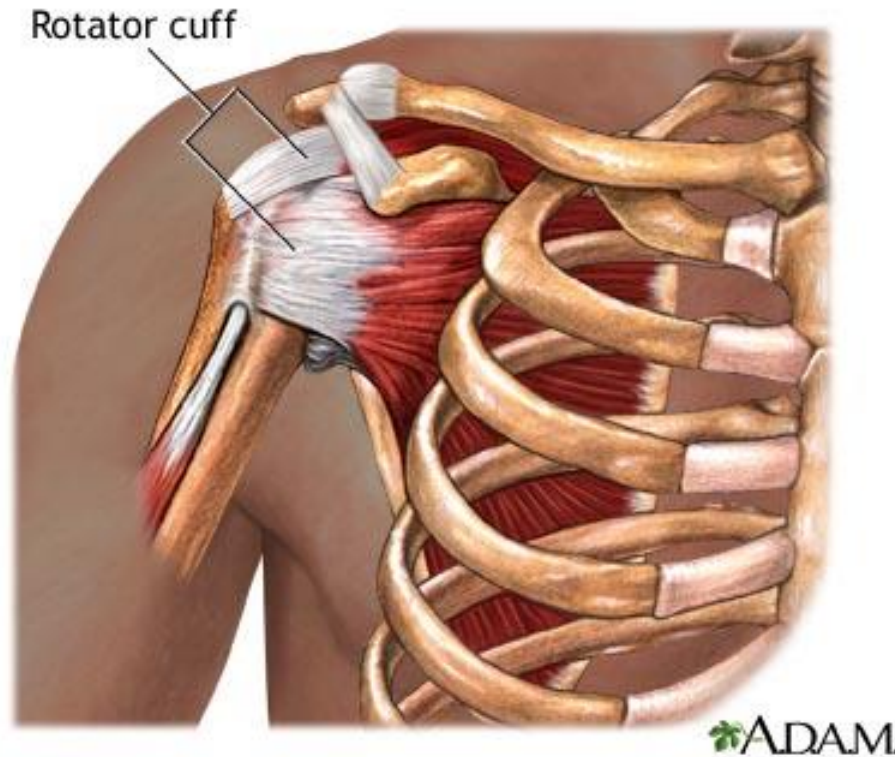




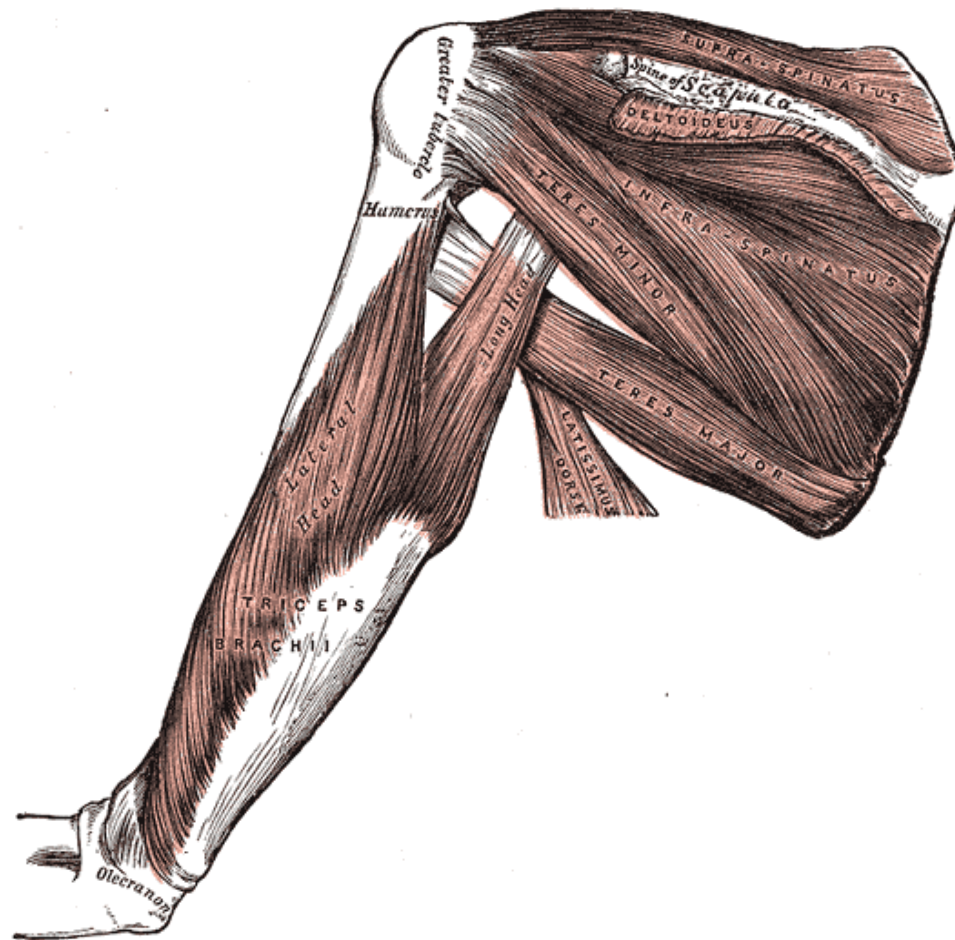
# Rotator cuff muscles



# Scapula, Humerus and Ribcage Anterior View



# Humerus and Scapula Posterior View



# Shoulder Girdle Muscle Questions

- Which muscle attaches from the EOP, superior nuchal line, nuchal ligament, spinous processes of C7-T12 *to the* lateral 1/3<sup>rd</sup> of the clavicle, acromion and spine of the scapula
  - Trapezius
- Which muscle attaches from the lateral 1/3<sup>rd</sup> of the clavicle, acromion and spine of the scapula *to the* deltoid tuberosity of the humerus
  - Deltoids
- Which muscle attaches from the spinous processes of C7-T5 *to the* medial border of the scapula from the root of the spine to the inferior angle
  - Rhomboids



# Shoulder Girdle Muscle Questions

- Which muscle attaches from the transverse processes of C1 through C4 *to the* medial border of the scapula from the root of the spine to the superior angle of the scapula
  - Levator scapula
- Which muscle attaches from the medial half of the clavicle, sternum, and costal cartilage of the ribs *to the* lateral lip of the bicipital groove of the humerus
  - Pectoralis major
- Which muscle attaches from ribs 3-5 *to the* coracoid process of the scapula
  - Pectoralis minor

# Shoulder Girdle Muscle Questions

- Which muscle has an insertion which is almost the same as another muscle's origin?
  - Trapezius and deltoids
- Which shoulder girdle muscle has an attachment on the coracoid process?
  - Pectoralis minor
- Which shoulder girdle muscle has an attachment on both the clavicle and the sternum (and the costal cartilage of the ribs)?
  - Pectoralis major
- Which shoulder girdle muscles can perform retraction of the scapula?
  - Rhomboids and middle trapezius
- Which two muscles abduct the arm at the shoulder joint?
  - Deltoids and supraspinatus

# Rotator Cuff Questions

- Rotator cuff muscles
  - What are the four rotator cuff muscles?
    - Supraspinatus
    - Infraspinatus
    - Teres minor
    - Subscapularis

# Rotator Cuff Questions

- Where do supraspinatus, infraspinatus and teres minor insert on the humerus?
  - Greater tubercle
- Where does subscapularis insert on the humerus?
  - Lesser tubercle
- Which two perform lateral rotation at the shoulder?
  - Infraspinatus and teres minor
- Which does medial rotation?
  - Subscapularis
- Which does abduction?
  - Supraspinatus

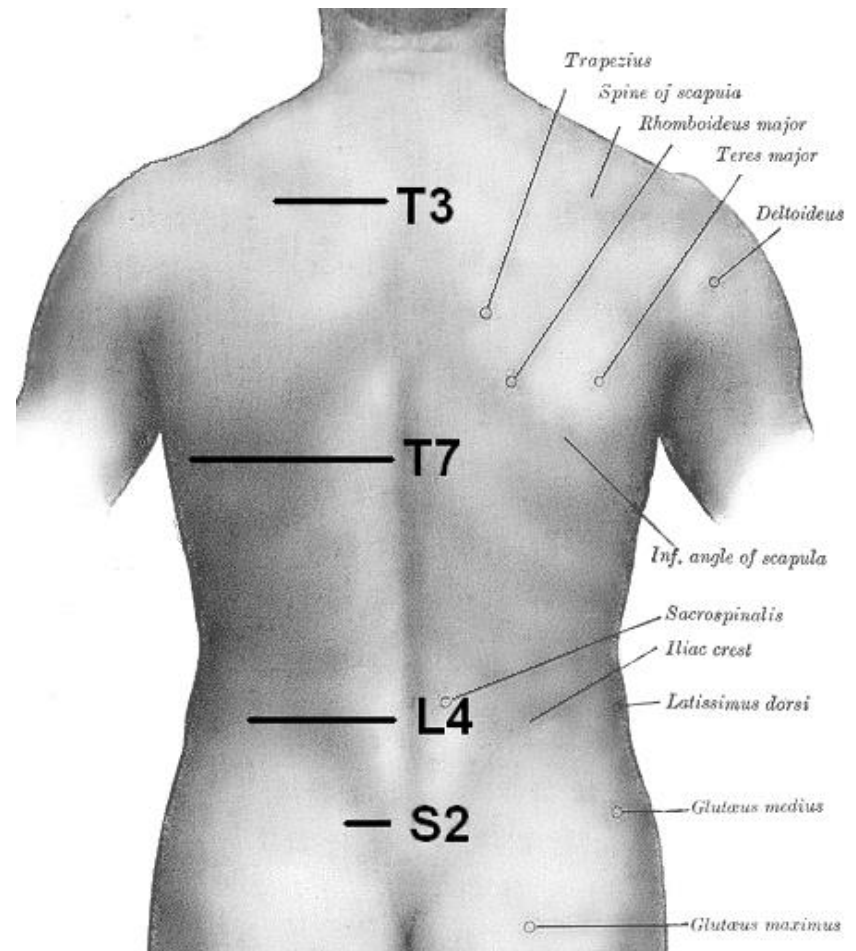
# Shoulder Girdle Landmarks and Vertebral Levels

*Includes a few other regions  
which will not be on test*

# Vertebral Levels and Landmarks

## (Especially Related to the Scapula)

- T1-T2
  - Superior Angle of the Scapula
- T3
  - Root of the Spine of the Scapula
- T7
  - Inferior Angle of the Scapula
- L4
  - Highest Point of the Iliac Crest
- S2
  - Posterior Superior Iliac Spine (PSIS)
- S3
  - Posterior Inferior Iliac Spine (PIIS)

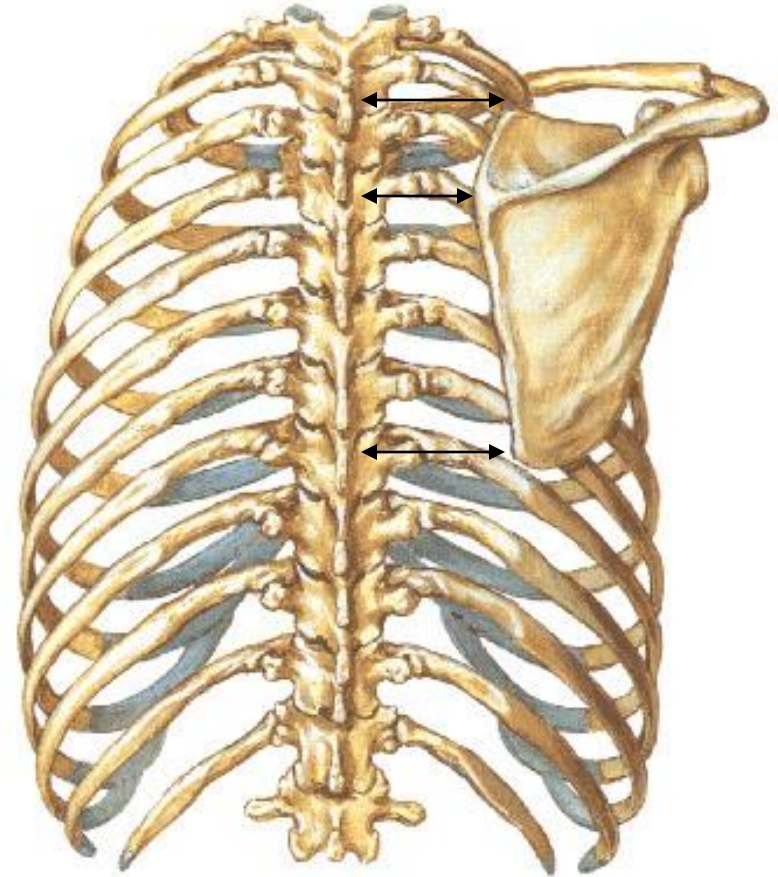




# Vertebral Levels and Landmarks

## (Especially Related to the Scapula)

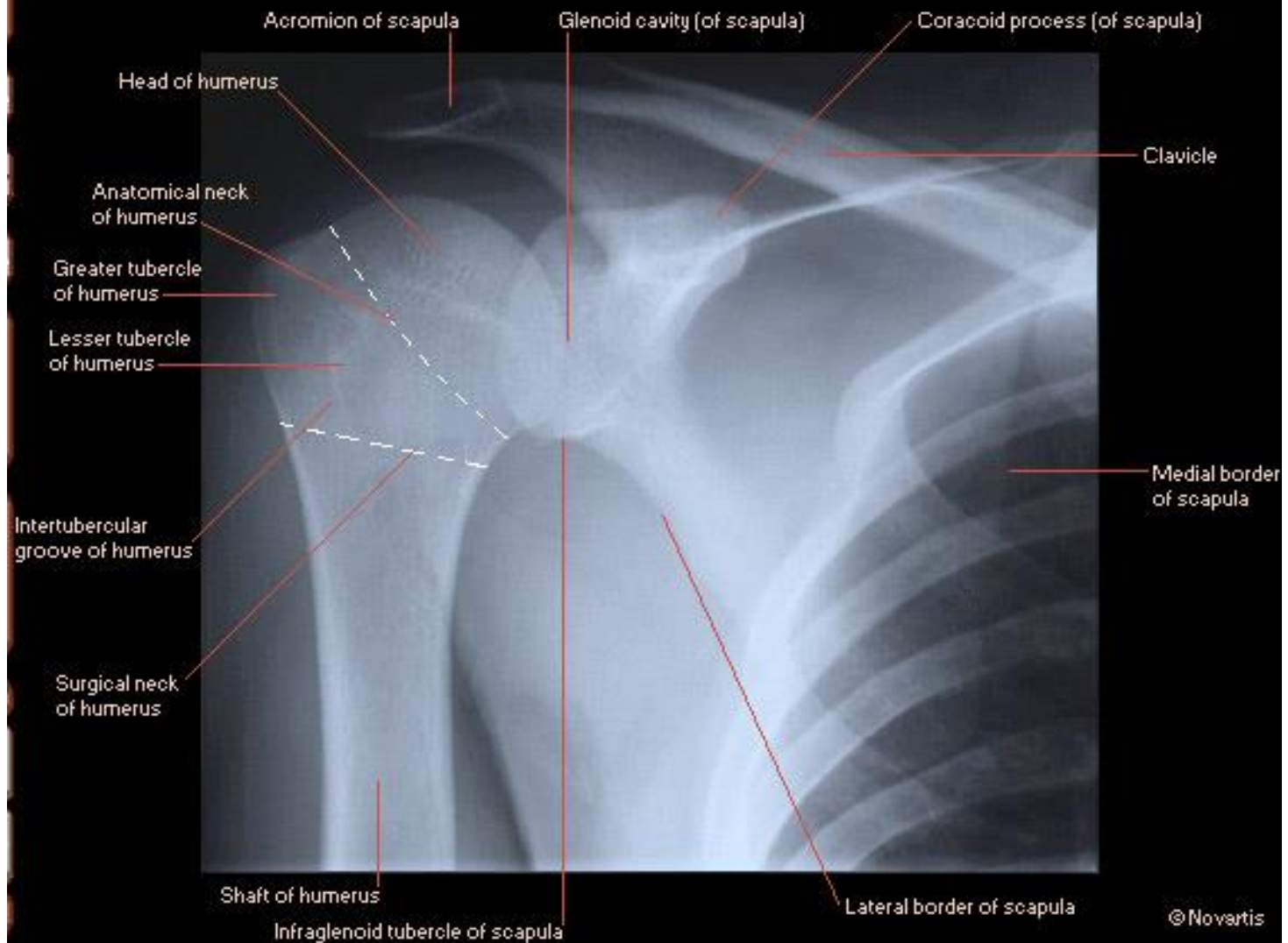
- T1-T2
  - Superior Angle of the Scapula
- T3
  - Root of the Spine of the Scapula
- T7
  - Inferior Angle of the Scapula
- L4
  - Highest Point of the Iliac Crest
- S2
  - Posterior Superior Iliac Spine (PSIS)
- S3
  - Posterior Inferior Iliac Spine (PIIS)



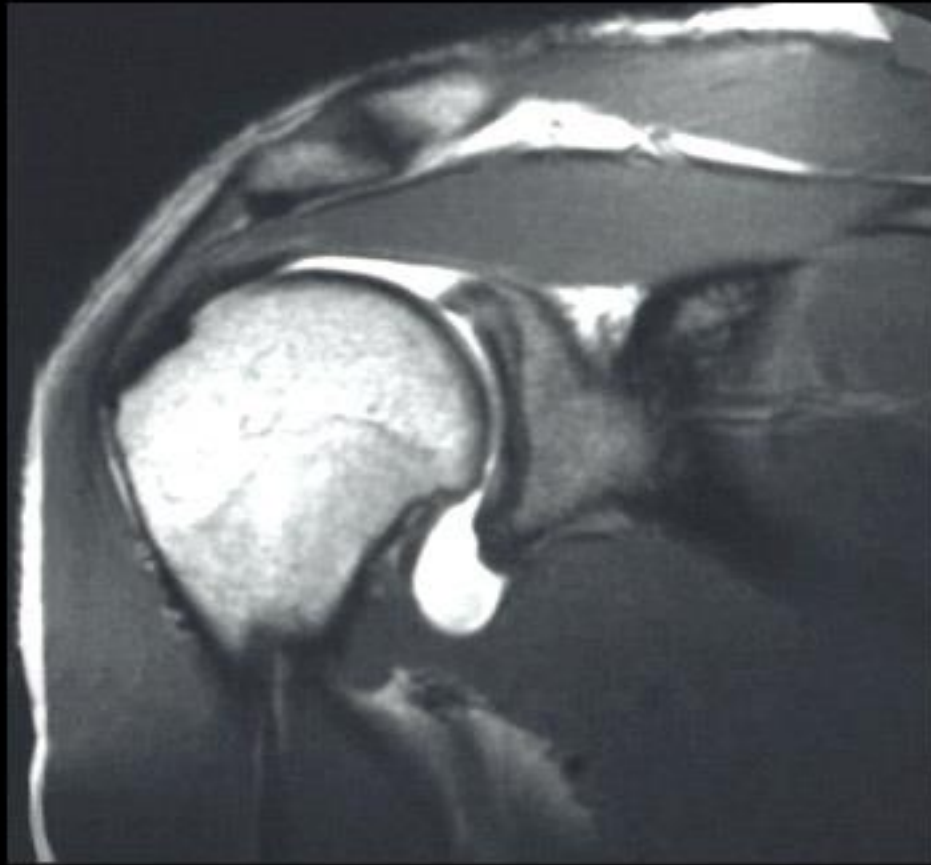# Imaging of the Shoulder

*Not on Test*

# Shoulder - Right Radiograph - AP View

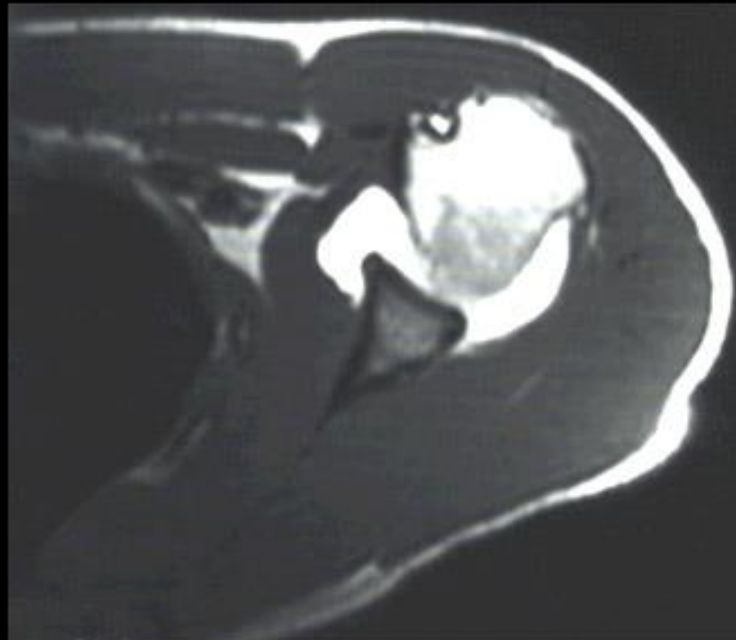

**Shoulder - Glenohumeral and Acromioclavicular Joints**  
MRI - Coronal Section



## Shoulder

MRI - Axial Section, Center of Left Humeral Head



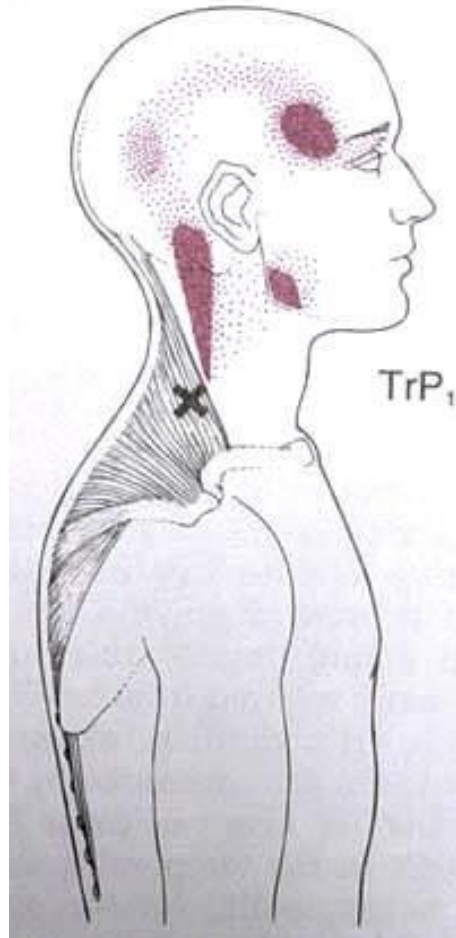
# Shoulder Girdle Muscles

Trigger Point Patterns

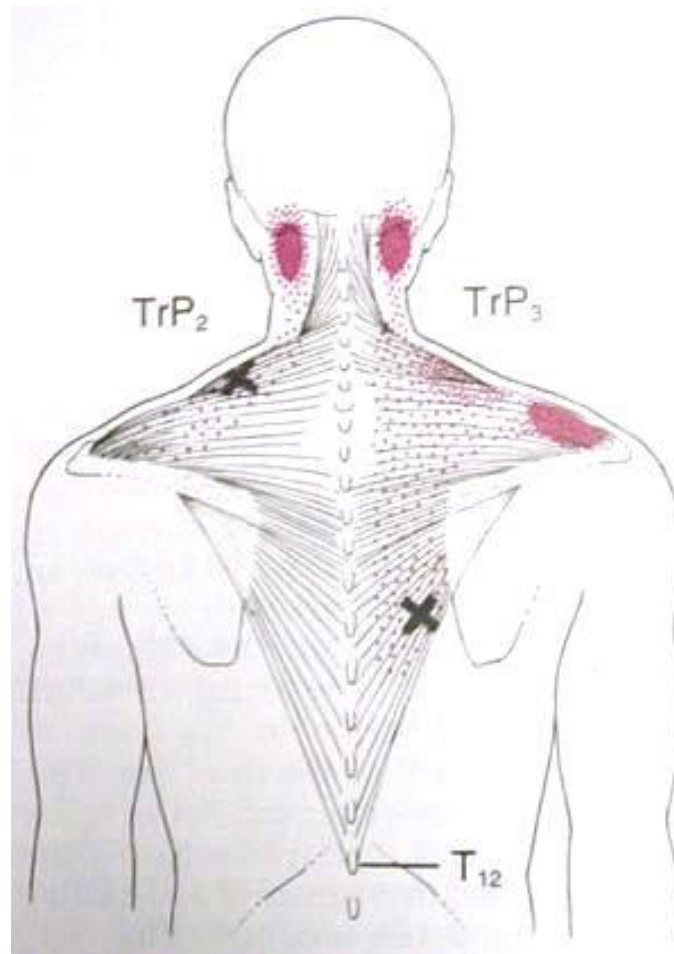
*Not on Test*



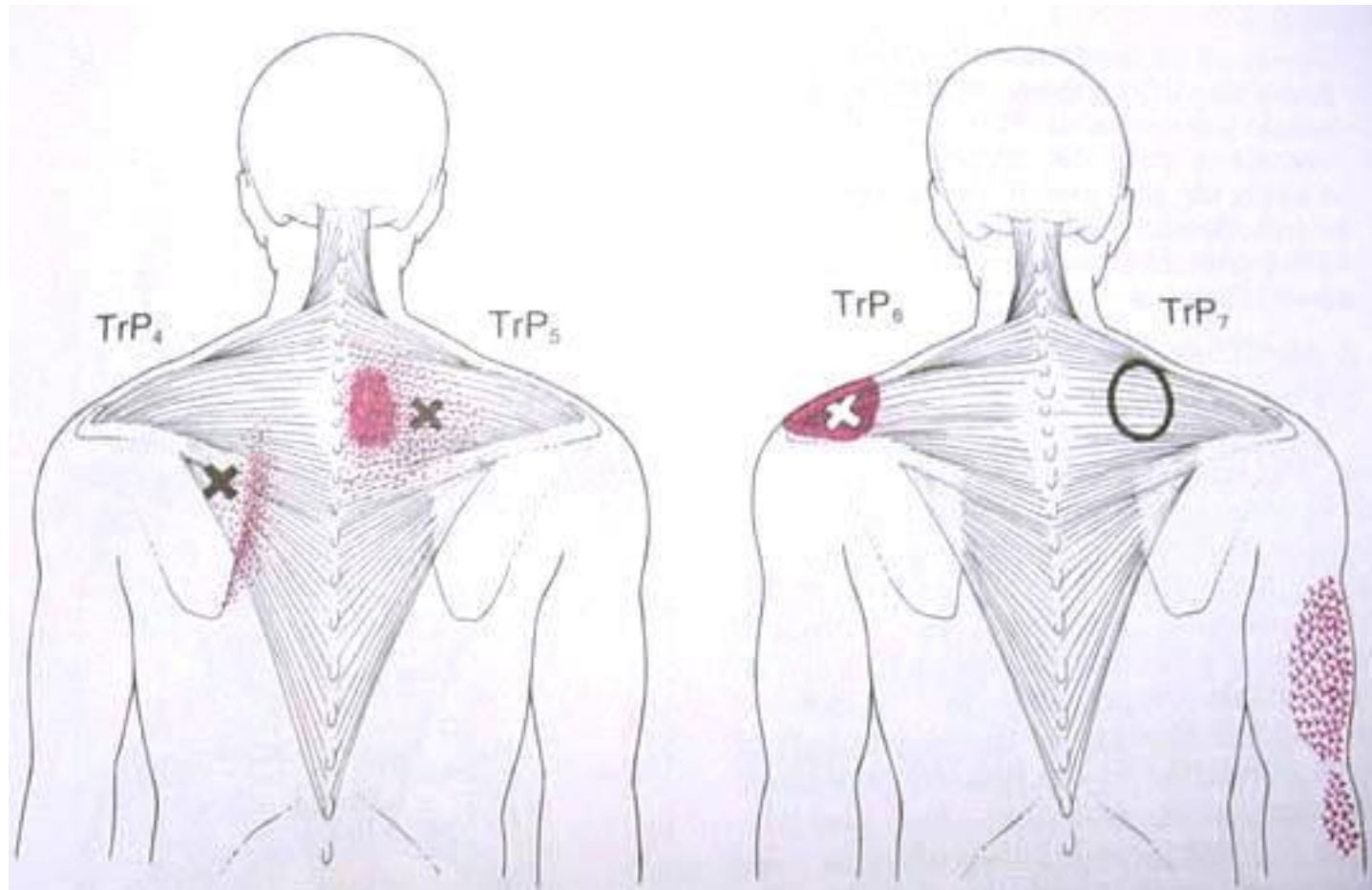
# Trapezius



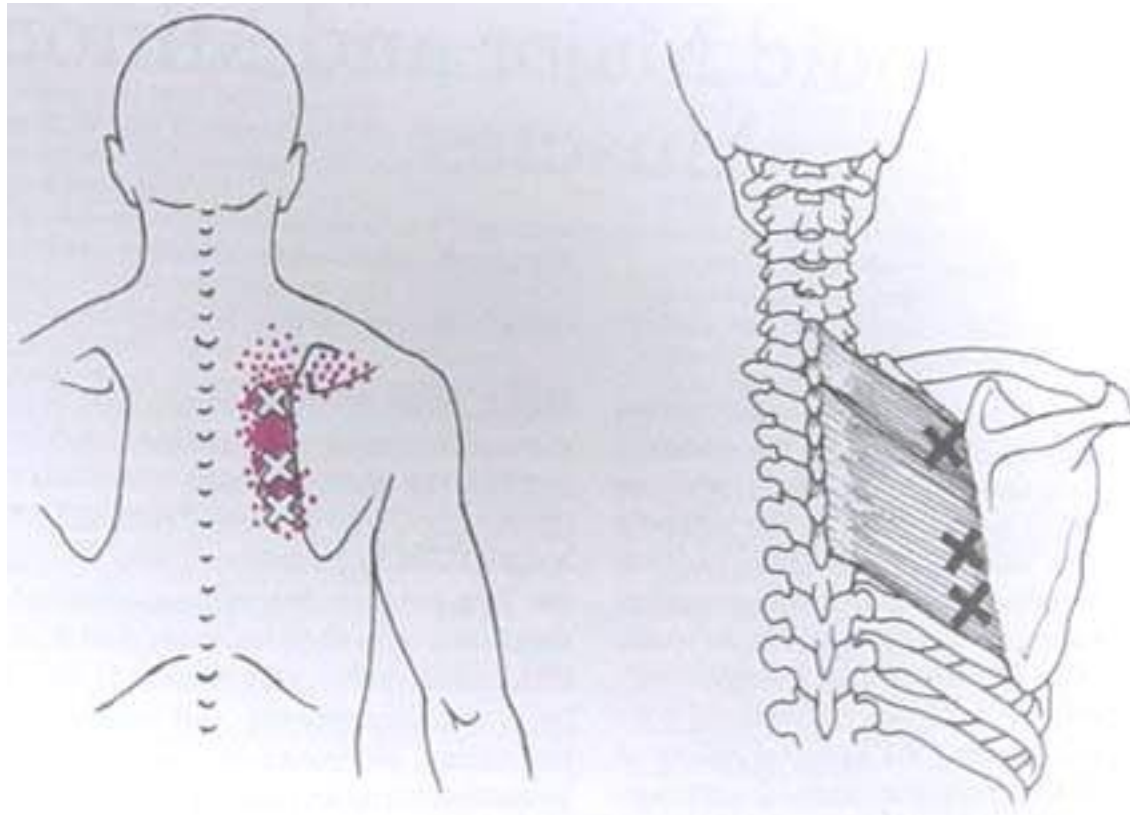
# Trapezius



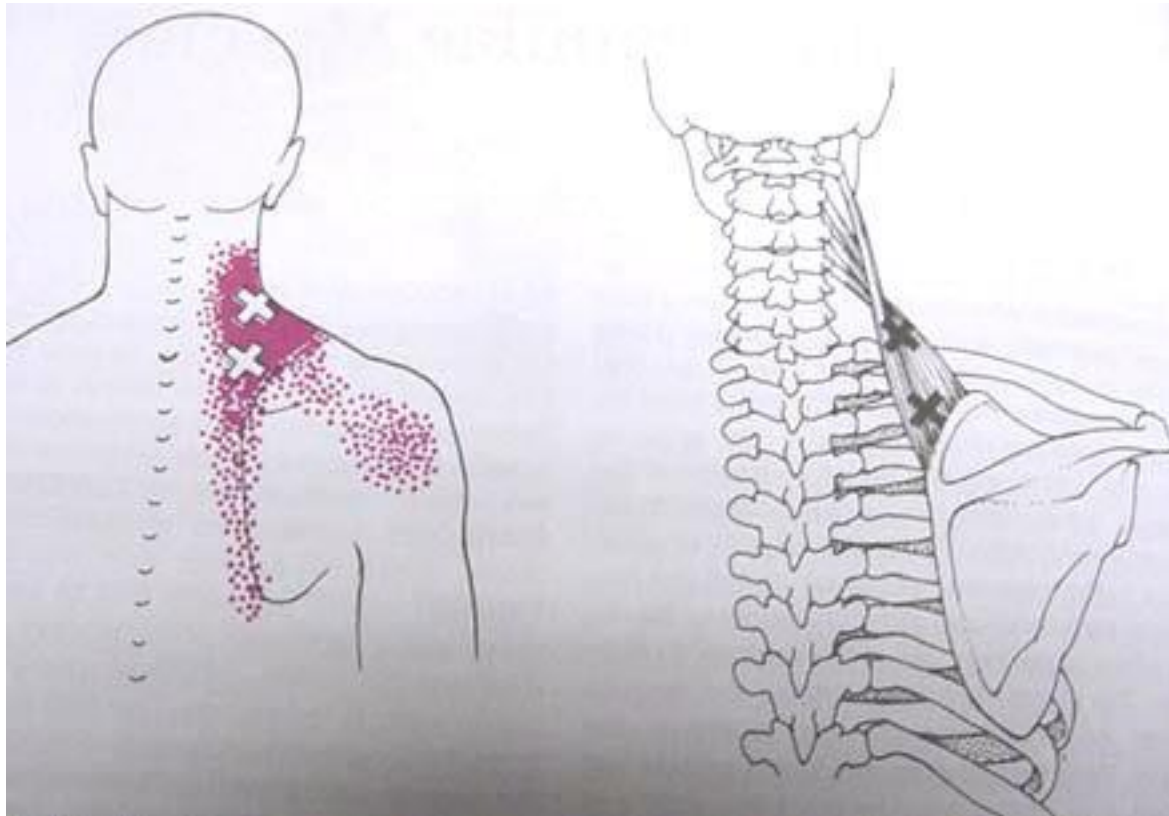
# Trapezius



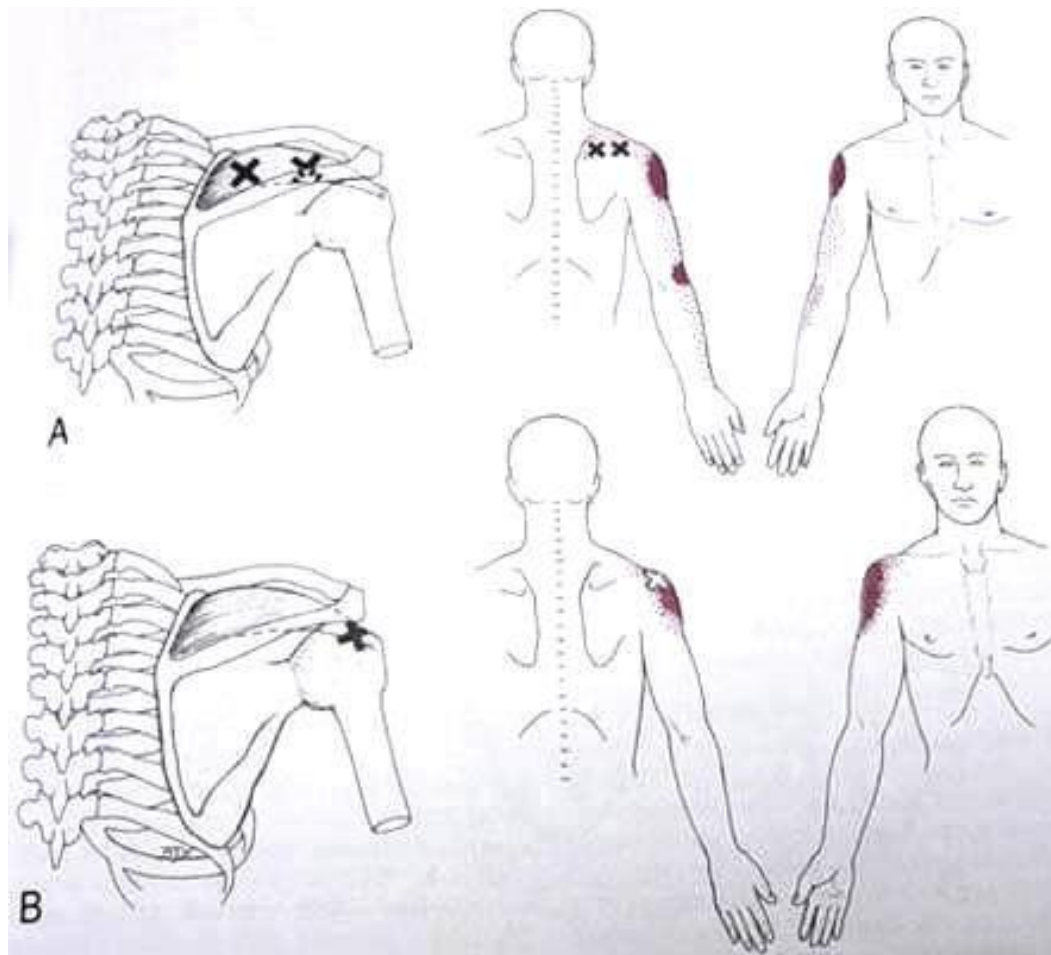
# Rhomboids



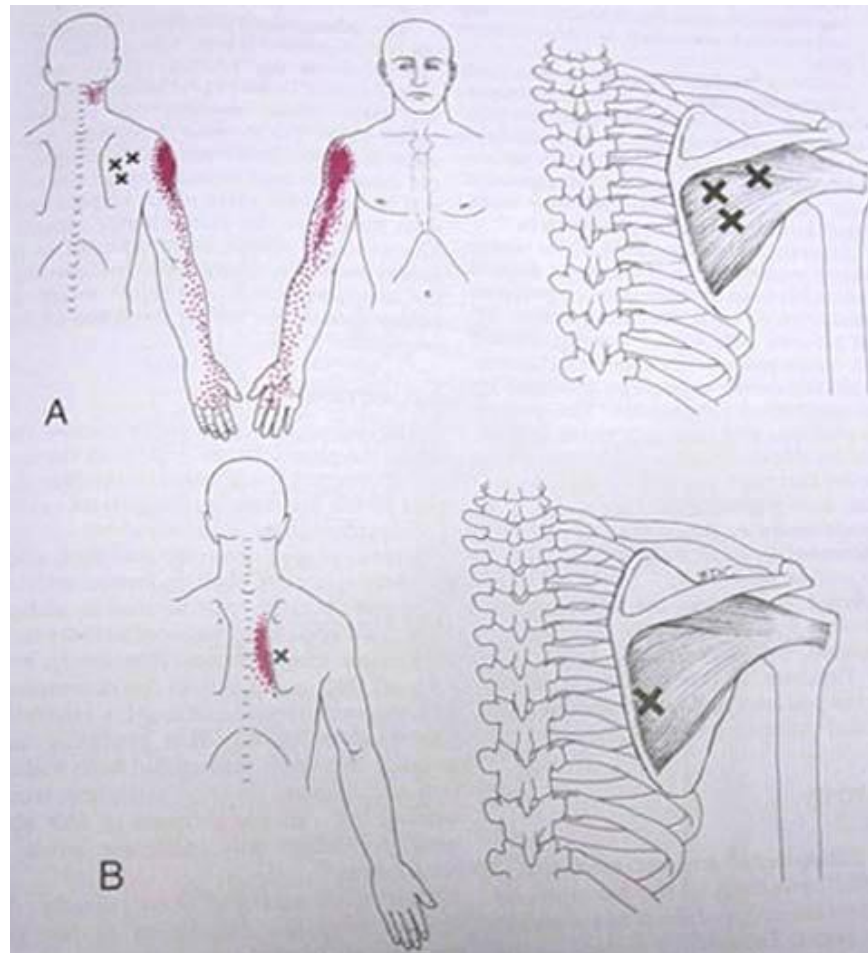
# Levator Scapula



# Supraspinatus

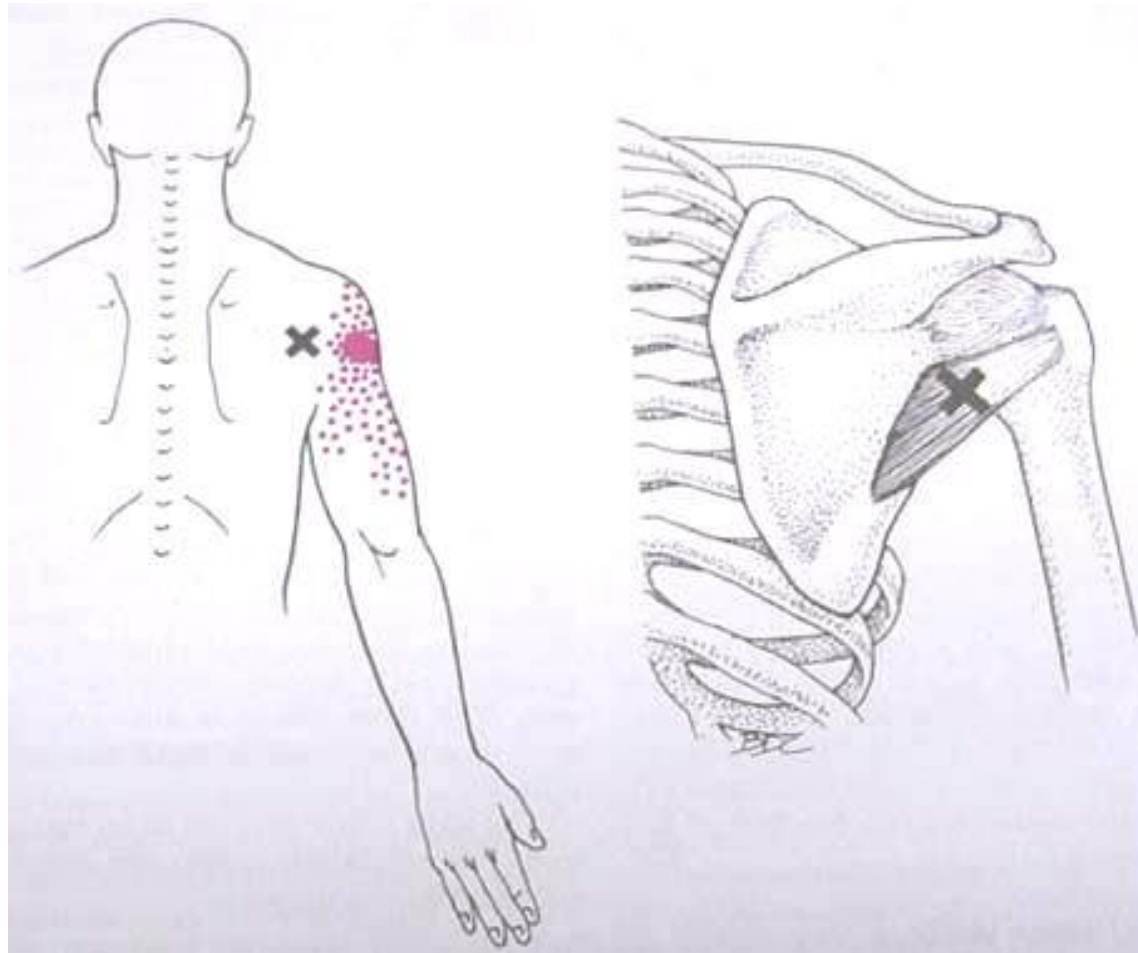


# Infraspinatus





# Teres Minor



# Subscapularis

